

The Individualized Component Face Lift: Developing a Systematic Approach to Facial Rejuvenation

Foot

Rod J. Rohrich, M.D.
Ashkan Ghavami, M.D.
Joshua A. Lemmon, M.D.
Spencer A. Brown, Ph.D.

AQ: 1

Dallas, Texas; and Beverly Hills, Calif.

Background: Accurate preoperative planning combined with facial fat compartment augmentation can improve precision and balance in facial rejuvenation techniques. Understanding the concept of “facial shaping” with respect to symmetry and soft-tissue (fat) distribution preoperatively is critical to optimizing aesthetic outcomes in various face lift techniques.

Methods: A review of 822 consecutive face lifts performed from January of 1994 to June of 2007 by a single surgeon (R.J.R.) was conducted. From this database, randomly selected cohorts of 50 preoperative and postoperative photographs were critically analyzed by three plastic surgeons exclusive of the senior surgeon (R.J.R.). Three facial parameters were compared on each facial side: facial height, degree of malar deflation, and orbit size. Long-term improvement was evaluated to delineate factors contributing to success in creating an aesthetically balanced facial shape.

Results: Asymmetry between the two facial sides was noted in every patient preoperatively with respect to the three study parameters and was improved postoperatively. There was no statistically significant interobserver bias in the evaluations ($p < 0.005$). Facial asymmetry dictated differential treatment of the superficial musculoaponeurotic system (SMAS) tissue between facial sides to achieve the desired youthful facial shape. The angle (vector) and extent of SMAS-stacking varied depending on the preoperative analysis. Similarly, the selection of SMAS-ectomy versus SMAS-stacking depended on the degree of malar deflation and resultant cheek fullness.

Conclusions: Proper preoperative analysis for evaluating facial shape should address (1) facial height, (2) facial width, and (3) overall distribution/location of facial fullness. This method of evaluating facial shape and symmetry is simple and reproducible, and can aid in formulating a comprehensive treatment plan. (*Plast. Reconstr. Surg.* 123: 1, 2009.)

M myriad techniques have been described that all share some form of superficial musculoaponeurotic system (SMAS) and fat-tissue repositioning (and/or filling) component.¹⁻¹⁷ Simple subcutaneous undermining and redraping may be effective in patients (often with some form of soft-tissue augmentation) who demonstrate good bony support and minimal soft-tissue deflation. However, the longevity and, thus, efficacy of these results are questionable.

Procedures that allow the SMAS to bear the load of the subcutaneous mass and overall soft-tissue ten-

sion and to be the principle factor in shaping may be associated with greater longevity.^{2,4,5,8} Sub-SMAS techniques, however, may be less reliable over time if an elevated thin SMAS (possibly containing iatrogenic perforations) is used as the load-bearing layer. Barton⁵ corrected this problem by changing the plane of dissection in the thinnest portion of the SMAS (medial to the zygomatic major muscle) to a subcutaneous plane. This redirects the tension on the overlying SMAS-subcutaneous skin, which serves to more effectively treat the anterior cheek tissue and nasolabial fold, as well as reduces

From the Department of Plastic Surgery, University of Texas Southwestern Medical Center, and private practice.

Received for publication October 8, 2008; accepted May 9, 2008.

Copyright ©2009 by the American Society of Plastic Surgeons

DOI: 10.1097/PRS.0b013e31819c91b0

Disclosure: None of the authors received financial benefit from any commercial entity in support of this article.

nerve injury near the zygomatic major muscle. Stuzin and colleagues^{9,15} use Vicryl mesh to help support the thinner, more unreliable SMAS region to reinforce the SMAS and provide stronger fixation to the malar periosteum. Plication and SMAS-ectomy face lift techniques also demonstrate improvement in facial contour, without complete release of all the implicated “retaining ligaments,”^{12–14,16,18,19} and may hold the true importance of these “retaining structures” up to scrutiny. Reports by Robbins et al.,¹ Baker,⁶ Saylan,¹³ Ansari,¹⁶ Webster et al.,^{18,19} and Tonnard and Verpaele¹⁴ attest to patient satisfaction from these “less invasive” face lift techniques.

Conceptually, an important question to consider is, *If facial fat and soft tissues have already been allowed to descend or deflate (through the aging process) beyond the retaining capacity of the so-called retaining ligaments, then why is it necessary to release all of these ligaments deep to the SMAS?* SMAS mobilization may not be limited as much as previously thought by these retaining structures, which themselves demonstrate a certain degree of inherent mobility and stretch, similar to mesenteries of the intestines. Furthermore, recent anatomic studies by Rohrich and Pessa²⁰ and Ghavami et al.²¹ have demonstrated that the presumed retaining systems of the face are functional membranes that separate numerous, well-defined fat compartments throughout the face, although perhaps serving a protective role for other facial structures. Some of the previously presumed retaining ligaments may simply be the fusion points of adjacent septa that define individual fat compartments.²⁰

The importance of accurate preoperative analysis in aesthetic surgery has been well established, particularly in the field of rhinoplasty.^{22,23} Facial rejuvenation is no exception, and detailed preoperative evaluation that improves balance in the aesthetic restoration of facial shape, as advocated by Stuzin et al.¹⁵ and Lambros,^{24,25} is as critical as it is in rhinoplasty. The use of systematic preoperative analysis in facial surgery is not widespread, yet it has transformed the field of rhinoplasty. Facial rejuvenation requires a similar revolution to minimize the sine qua non “face-lifted appearance” that is prevalent in social settings and negatively influences public’s opinion.

This article presents the senior author’s (R.J.R.) 13-year experience with a rhytidectomy technique that has developed concomitantly with concepts in facial shaping and proper preoperative evaluation. The concepts of deep layer manipulation by SMAS-ectomy (SMAS excision/advancement) or SMAS incision/limited undermining/advance-

ment (“SMAS-stacking”) and the effect of direction of pull as they pertain to proper preoperative facial analysis and resultant facial shape are delineated. Analysis focused on three basic facial parameters (Fig. 1):

- (1) *Midface width*: determined by a horizontal line through the infraorbital rims
- (2) *Facial length*: vertical height from the malar projection point to the inferior jowl point
- (3) *Facial fullness*: overall distribution of soft-tissue fullness

Attention to facial asymmetry provides a reference point within each face to compare the wide/full side versus the narrow side, and the long versus the short facial side. (Note: Although correction of asymmetry is not a primary goal, its recognition serves to draw focus to the individual features that contribute to facial shape.) No measurements are needed, which simplifies this analysis.

ANATOMY

The SMAS is the investing fascia of the mimetic muscles of the face and is continuous with the platysma inferiorly and temporal-parietal or superficial temporal fascia superiorly.^{26–29} It lies deep to the facial fatty layer (subcutaneous fat), yet is firmly adherent to the parotid fascia laterally, where it is known as the immobile SMAS. Anterior to the parotid gland, a looser areolar plane lies

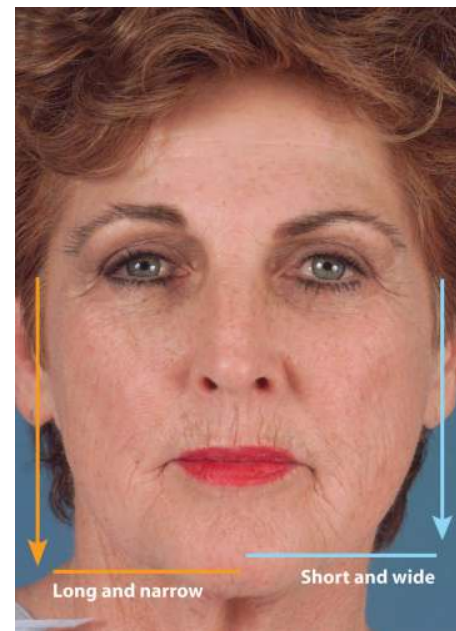


Fig. 1. Preoperative analysis for individualized component face lift. Anteroposterior view used to determine midface width, height, and overall facial shape and soft-tissue distribution.

F1

AQ: 2

beneath the SMAS, which allows for gliding of the more mobile anterior SMAS region.^{27,29} Transmitting through this layer to the overlying musculature are numerous ligaments that are themselves more mobile in specific topographical regions (lateral brow, inferolateral orbit) and more fixed/taut in others (medial mandibular border, medial orbit).^{21,28,29}

Ghavami et al.²¹ have recently shown that the more lateral orbicularis retaining ligament is longer and more lax relative to its medial portion, which may help explain why one observes lateral brow hooding and lateral “malar crescent”⁴ formation, and why these processes do not occur medially. One solution to this problem may be the use of techniques that suspend the orbicularis retaining ligament to reshape the lateral periorbital.²¹ Rohrich and Pessa²⁰ postulate that these ligaments and other “retaining structures” act as diffusion barriers between one facial fat compartment and another to accommodate edema and other fluid influx/efflux (blood, infection).

Rhytidectomy techniques that involve SMAS undermining may allow for increased mobilization of the SMAS layer and the looser fascial fatty layer superficial to it through separation of the retaining ligaments present at the zygomatic arch, the mandibular border, and the anterior border of the masseter.^{28,29} These methods can produce excellent results, but this additional SMAS mobilization may not always clinically translate to results that are superior to SMAS-ectomy or SMAS-plication techniques.^{6,13,14,18,19}

PATIENT EVALUATION AND AESTHETIC GOALS

Patterns of aging can be clearly seen in the midface. Skeletal changes,^{32–34} volume loss,^{24,25,35} and gravitational descent (less important) occur with age and coalesce to create an overall “aged” facial appearance. The transition points between subcutaneous and deep fat compartments demarcate their anatomical borders, resulting in visible folds (nasolabial region, malar fold), lines (nasojugal groove), and areas of soft-tissue overhang (malar crescents, jowls). The subcutaneous cheek mass deflates and becomes more prominent anteriorly over the anatomic shelf of the nasolabial fold, which is fixed medially.³⁶ This produces the appearance of progressive nasolabial crease depth and a lateral nasolabial or midmalar fold of subcutaneous tissue. When combined with midfacial fat atrophy, a square facial contour results and helps explain the concept of “radial expansion.”^{9,37} When the midface remains fuller laterally, with limited

soft-tissue atrophy, the face assumes a round appearance.

The process of facial aging rarely, if ever, renders proportionate changes in an individual patient and may be due in large part to precisely defined processes that age the numerous “facial fat compartments.”^{20,21} It is not uncommon to identify asymmetries that actually become unmasked and more prevalent through facial aging and should be pointed out to patients. Differential bony prominences and soft-tissue fullness create imbalances in the appearance of malar fullness and width which may be greater on one side, whereas lower facial fat that is more flat becomes more prevalent on the contralateral side.

Surgical technique should be directed toward specific aesthetic goals that center on component facial “shaping” and “filling.” These goals are restoration of an angular facial contour (jawline) and facial highlights, recreation of malar fullness relative to a submalar depression (hollowing), and reduction of facial shape asymmetry between facial sides. Proper preoperative clinical analysis permits accurate detection of recurrent patterns of aging and facial contour changes, which in turn serves as the preliminary point to which further technical maneuvers can be built upon.^[38]

AQ: 3

METHODS

A database of 822 consecutive face lifts performed from January of 1994 through June of 2007 by a single surgeon (R.J.R.) was constructed and a cohort of 50 patients was randomly selected. Care was taken to duplicate the original 50 subjects to produce a “set of 100 subjects” to analyze. This was done to delineate any interobserver score variations and to improve the statistical power of the study. Preoperative and postoperative photographs were analyzed by three different plastic surgeons using a graded scoring system.

Three facial parameters were analyzed on each facial side: facial width, facial length, and the side with the larger orbit. In addition, overall preoperative and postoperative asymmetry scores were assigned. The facial width was assessed with the width at the infraorbital rims as the reference point. This represents the overall malar width and fullness in the anteroposterior view. Length was determined from the infraorbital rim to the most inferior point of jowl formation. The magnitude of each of these parameters preoperatively and the degree of improvement postoperatively were graded using a numerical system ranging from 1 to 4, with 1 denoting none, 2 minimal, 3 moderate, and 4 severe asymmetry. The score of none implies

only slight asymmetry and was deemed to be clinically insignificant (not requiring surgical correction). Results were tabulated using Kruskal-Wallis and Friedman analyses of the 100 data sets to evaluate for any statistical bias among the surgeons. Overall improvement in these parameters at 1 year after rhytidectomy was used as a marker of success in achieving an aesthetically pleasing facial shape and contour.

RESULTS

Based on this large review of one surgeon's (R.J.R.) experience with individualized component face lift, a system of preoperative evaluation was delineated based on facial shape analysis. The corresponding surgical technique of SMAS shaping was outlined as it corresponded to preoperative facial shape and symmetry. There was

no statistical bias ($p < 0.005$) among the three surgeons' assessment of facial shape asymmetry, height, width, and the larger orbital aperture ($p < 0.05$). Orbital aperture was useful as a secondary soft sign and seemed to correlate with the longer facial side.

The overall method of analysis was simple and reproducible. Furthermore, statistically significant improvement ($p < 0.05$) in asymmetry and aesthetic facial rejuvenation was achieved based on the summed reviewer scores. The summed scores from postoperative evaluations from the three reviewers were 1.63, 1.9, and 1.79 (asymmetry grades 1 to 4), suggesting marked improvement in postoperative facial shape and symmetry. The percentage improvement from preoperative to postoperative asymmetry scores is illustrated in Figures 2 and 3.

F23

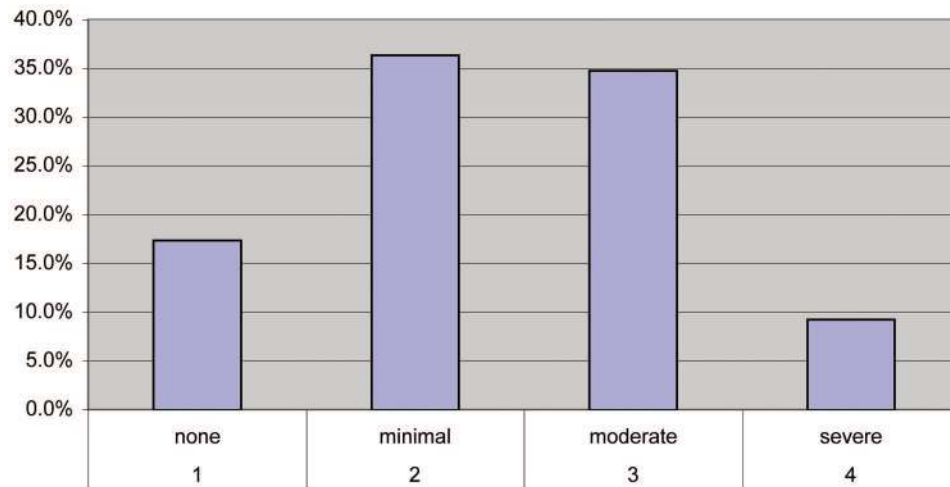


Fig. 2. Preoperative evaluation of facial shape asymmetry.

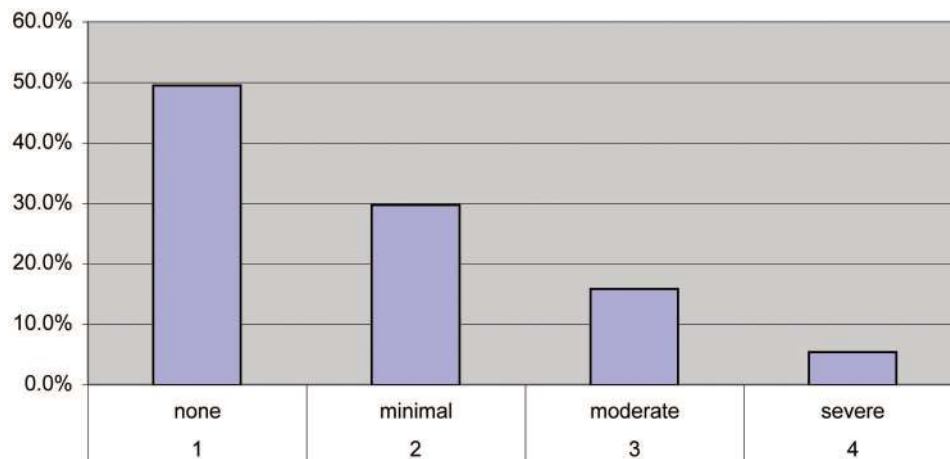


Fig. 3. Postoperative evaluation of facial shape asymmetry. Note the improvement in overall asymmetry scores after the individualized component face lift technique.

Skin Undermining

T1

The skin is undermined in the subcutaneous plane to expose the underlying fat compartments and SMAS. The differential skin undermining and SMAS treatment allow for a more natural redistribution of skin at closure. The direction of skin redraping is not obligated to follow the same vector of SMAS manipulation, which is a disadvantage of skin-SMAS unit techniques. The extent of skin undermining is determined preoperatively and is based mostly on the facial (malar) width (Table 1). The amount of undermining can be extended, if necessary, during and after SMAS treatment based on any skin irregularities, such as dimpling/tethering or displeasing contour. It is important to start out with less undermining because excessive undermining is irreversible, can distort the oral commissure, and may work against the intended facial shaping. The skin is undermined at a minimum to the most anterior edge of the planned SMAS-ectomy or SMAS-incision/undermining/stacking line.

“Limited” undermining is defined as lateral to the lateral canthal region and is indicated in wide faces. In addition, skin undermining should not extend anterior (medial) to the lateral canthus if a “horizontally” angled SMAS-ectomy or SMAS-stacking is planned. This allows the inferiorly located cheek fullness to remain attached to the skin flap in the precise location that needs the most vertical mobility. The resultant effect is greater malar projection and submalar hollowing, prevention of excess malar width, and improvement of the wide jawline (wide jowls).

“Extended” undermining is defined as medial to the zygomatic major origin and lateral canthus. Overall, when the midface is narrow, more undermining is required. This allows access to the more medial SMAS and fat compartments. The soft tissue in this region can now be moved a greater distance in an oblique fashion (perpen-

dicular to the nasolabial fold). This improves malar width and overall cheek fullness. Extended undermining is also necessary when significant skin redundancy is found medial to the lateral canthus, commonly present in patients with jowling that is located more inferiorly, pronounced marionette lines, and after massive weight loss. Low-set jowls help define the longer facial side, which is commonly the narrower side.

Facial Fullness (Midface Width)

SMAS-ectomy is performed to debulk the submalar region when the midface is full or wide. The shorter midfacial side tends to also be the fuller side. Generalized fullness or round faces, however, can present in long faces, which also dictate SMAS-ectomy. Preoperative evaluation of facial length will dictate the orientation or angle of the SMAS shaping and the direction of SMAS movement (Table 2 and Fig. 4).

T2,F4

When performing SMAS-stacking, the SMAS is incised, undermined proximally and distally, and then advanced toward a central axis line (Fig. 5). As the incised/undermined edges are brought over the remaining SMAS base, a three-layered stacking effect is produced, which enhances malar projection and cheek fullness. The exact location in which the SMAS is incised is important. More facial augmentation can be performed with adjunctive fat augmentation. Stuzin et al.’s technique^{9,15} folds the SMAS upon itself in this region to create a similar effect. The amount of SMAS incorporated in each individual suture bite will also add to the fullness. Taking larger bites or more numerous bites of SMAS serves to further augment tissue. Using finesse in “spot plication” will help balance overall midface shape by blending contour transition points to decrease lumpiness and irregularities.

F5

The underlying skeletal support also plays a role in determining facial shaping goals. A patient who has strong skeletal support, evidenced by greater interzygomatic width and more promi-

Table 1. Individualized Component Face Lift Undermining and SMAS-ectomy versus SMAS-stacking

| Midface Analysis (length/width) | Skin Undermining Extent | Stacking* versus SMAS-ectomy |
|---------------------------------|-------------------------|------------------------------|
| Long/narrow | Extended† | SMAS-stacking |
| Short/wide | Limited‡ | SMAS-ectomy |
| Long/wide (uncommon) | Limited | SMAS-ectomy |
| Short/narrow | Extended | SMAS-stacking |

*SMAS-stacking refers to SMAS incision, limited undermining, advancement, and resuturing to stack the three SMAS layers.
 †Extended: medial to zygomatic major muscle and lateral canthus.
 ‡Limited: Does not extend medial to lateral canthus.

Table 2. Individualized Component Face Lift—SMAS Shaping

| Midface Analysis (length/width) | SMAS Shaping Angle |
|---------------------------------|--------------------|
| Long/narrow | Oblique* |
| Short/wide | Horizontal† |
| Long/wide (uncommon) | Horizontal |
| Short/narrow | Oblique |

*Oblique is defined as parallel to nasolabial fold. SMAS moves obliquely.
 †Horizontal is defined as parallel to orbital rim line. SMAS motion is vertical.

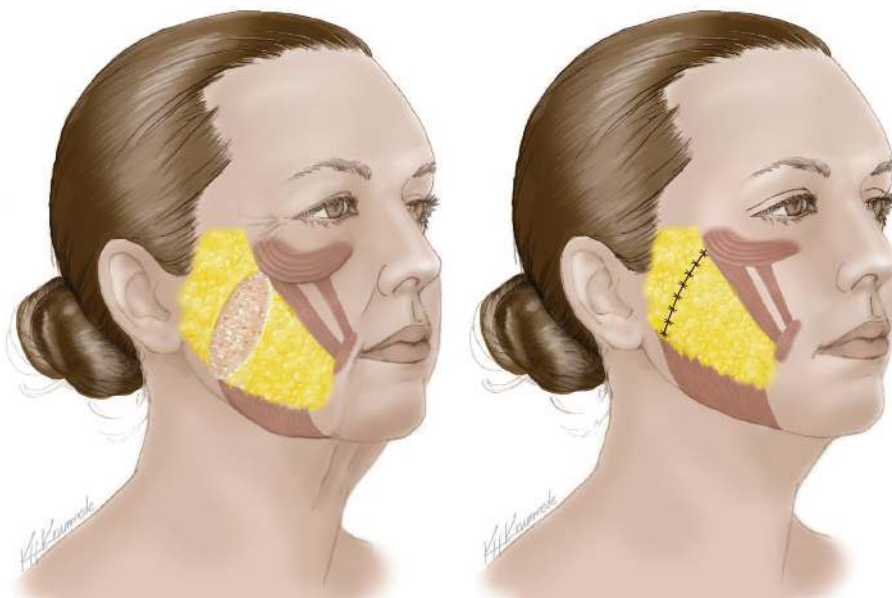

Fig. 4. Oblique SMAS-ectomy. SMAS movement is directed perpendicular to the nasolabial fold. This is beneficial for the narrower facial side.

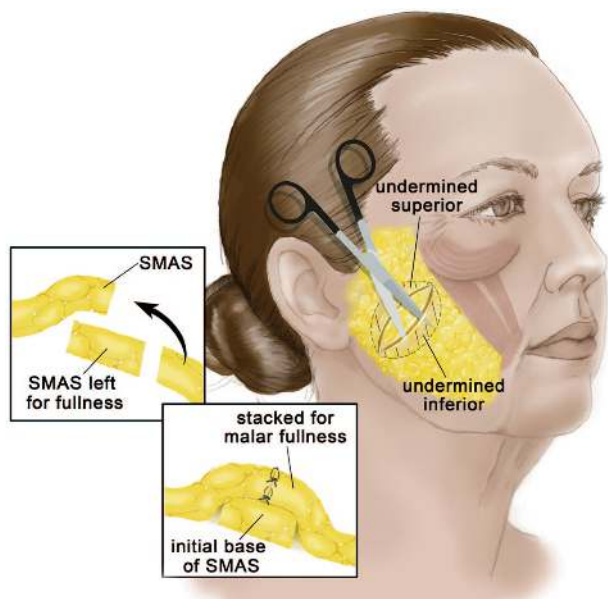


Fig. 5. SMAS-stacking. SMAS incision and plication serves to *stack* tissue in the direction that the SMAS is lifted. The SMAS base remains while limited proximal and distal SMAS undermining allows the surgeon to create a three-layered construct. This is beneficial in narrow faces that need more fullness in the malar region. The orientation of the SMAS-stacking will dictate where this augmentation is produced.

ment malar eminences, may not require as much SMAS-stacking over the lateral malar region. This type of facial shape would benefit from a horizontally directed SMAS layering or SMAS-ectomy that mobilizes tissue in a vertical direction.

Facial Length (Height)

Difference in facial length must be recognized, because altering the direction of SMAS motion can balance out the final facial shape. Malar highlights tend to be located more superior on the longer facial side, resulting in more pronounced submalar hollowing and a “narrow” midface. A long/narrow or short/narrow facial shape requires an oblique direction of pull to avoid creating excessive submalar hollowing and to distribute soft-tissue fullness more laterally, where it will provide an overall increase in midface width. This is commonly used in elderly patients along with SMAS-stacking because more bulk is needed in the submalar region and more overall facial fullness is desirable. The SMAS incision is designed parallel to the nasolabial fold, which permits obliquely oriented SMAS movement.

When the face (or facial side) is short/wide or long/wide (uncommon), a horizontal orientation of SMAS excision is designed to permit vertical SMAS advancement over the malar eminence, which results in enhanced submalar hollowing at the buccal recess (Fig. 6). As more SMAS is recruited superiorly in the short/wide face, the fat compartments that are medial to the zygomatic major become compressed into the superior portion of the buccal recess, which creates improved submalar hollowing. If the SMAS is moved obliquely in a short face, then excessive width and fullness will create a short and round face, which is not a desirable goal in facial contouring. Occa-

F6

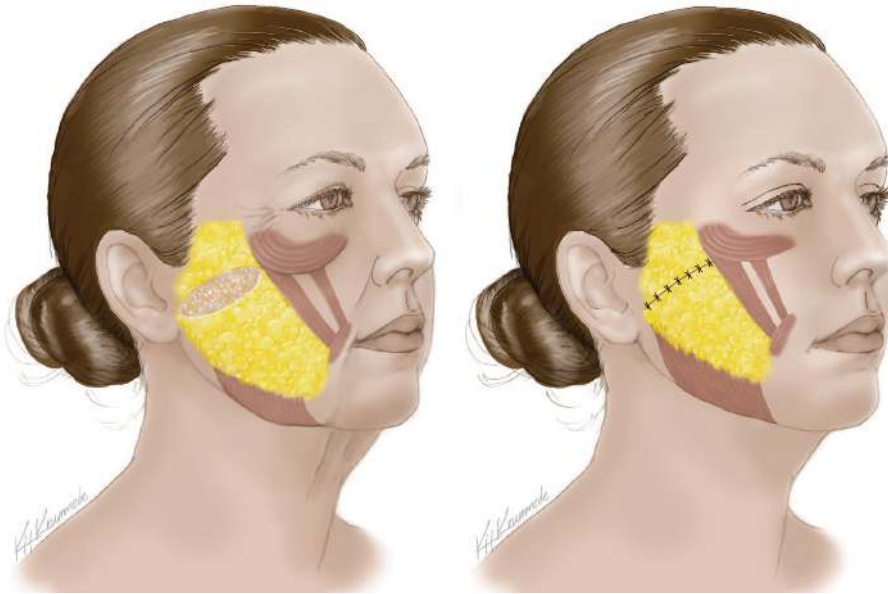

Fig. 6. Horizontal SMAS-ectomy. SMAS-ectomy is oriented horizontally so that the SMAS moves in a vertical direction. This recruits more tissue superiorly, thereby increasing medial malar fullness while creating a relative submalar hollowing. This technique is used for the wide midface so that excessive width is not recruited laterally, where it is not needed.

AQ: 4 sionally, the long facial side can be the wider side if it is treated by a horizontal SMAS-ectomy and vertical SMAS movement.

When SMAS-ectomy or SMAS-stacking is performed, the fascial-fatty layer and underlying SMAS are divided full thickness. Care is taken to

preserve the underlying deep fascia overlying the parenchyma of the parotid gland, buccal fat pad, and masseter muscle. Violation of this deep fascia places the underlying facial nerve at risk and can also lead to pseudoherniation or true herniation of the buccal fat, which produces contour irreg-

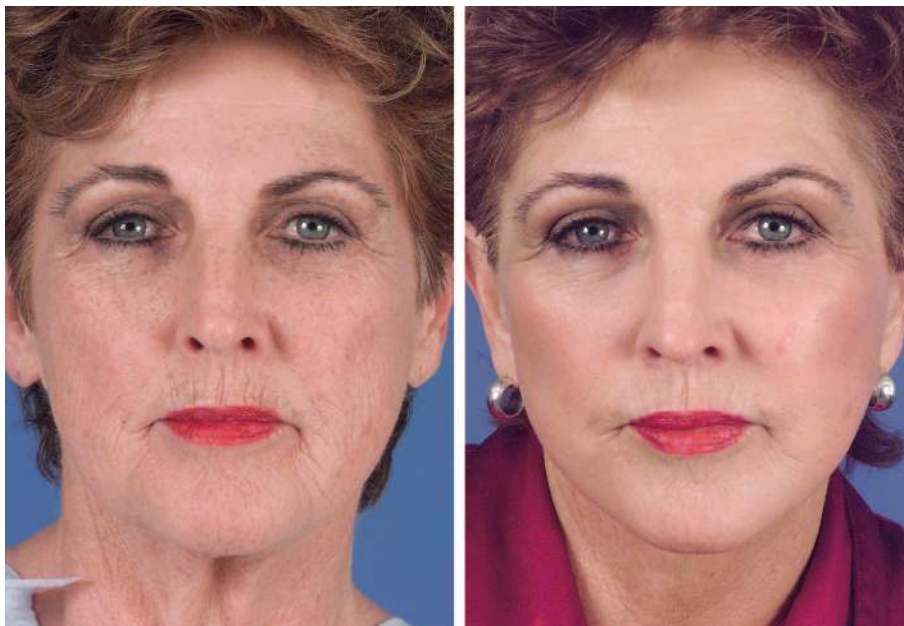

Fig. 7. Case 1. Preoperative and postoperative views of a 64-year-old woman with moderate facial shape asymmetry.

ularities. It is not necessary to undermine the divided edges of the SMAS. The anterior mobile SMAS advances without undermining and is secured to the immobile SMAS because of the inherent laxity of the “retaining structures.”

CASE REPORTS

Case 1

A 64-year-old patient presented with moderate facial shape asymmetry. Her right side was long and narrow (more inferiorly

located jowl) relative to the left facial side, which was shorter and wider. There was a larger orbital volume on the right side, coinciding with the longer facial side. Overall, she demonstrated a disharmonious facial contour that required differential treatment of the right and left SMAS to create a more pleasing malar-to-submalar relationship and to establish overall facial angularity with symmetry. Her operative plan included an individualized component face lift and an open neck lift (platysmaplasty). For the individualized component face lift technique, less undermining was necessary on her left side compared with her right; SMAS-ectomy was performed on the left side to reduce midface fullness, and a minimal SMAS excision

AQ: 5

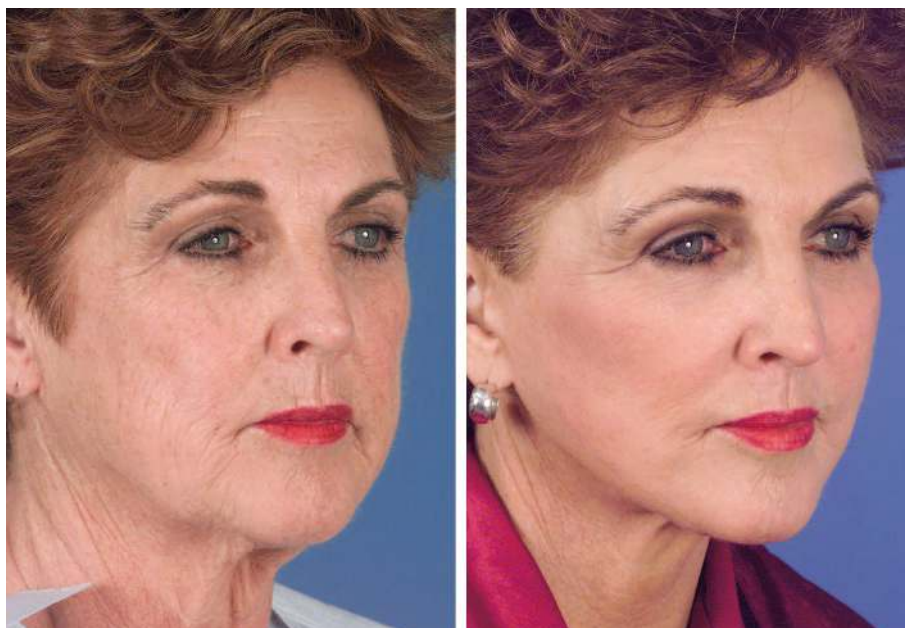

Fig. 8. Case 1. Additional views of the patient shown in Figure 7.

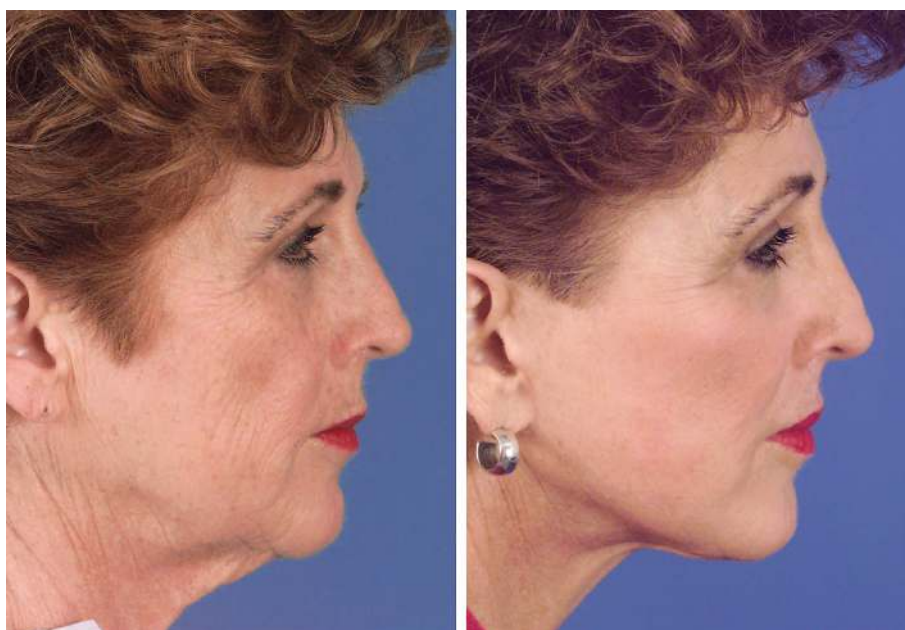

Fig. 9. Case 1. Additional views of the patient shown in Figures 7 and 8.

Volume 123, Number 3 • Individualized Component Face Lifts

was used on the right side to balance the facial fullness. Horizontal SMAS-ectomy with vertical SMAS repositioning was used on the left to move the inferior cheek tissue more superiorly and create a submalar hollowing. The right SMAS was obliquely oriented to establish greater midface width on the narrower side. Other procedures included quad-blepharoplasty, fat augmentation of the nasolabial fat compartment, and full-face laser skin resurfacing (Figures 7 through 9).

F7-9

Case 2

A 56-year-old patient presented with overall facial fullness and moderate asymmetry. Her right midface was fuller and shorter. The left side was long and narrow. Her left orbital cavity was larger, with brow and upper lid crease asymmetry present (Fig. 10). Her operative plan included an individualized component face lift, neck lift, fat augmentation to the medial nasolabial fat compartment, quad-blepharoplasty, and hyaluronic acid filling of the upper and lower vermillion. The individual-

F10

ized component face lift technique, more extended undermining was used on the left; SMAS-ectomy was performed bilaterally to reduce facial fullness; and vertical SMAS movement (horizontal SMAS-ectomy angle) was used on the right and more oblique vector on the left to improve facial balance and to create greater malar width on the left. In other procedures, orbital asymmetry was camouflaged with an asymmetric upper blepharoplasty.

AQ: 6

Case 3

A 44-year-old woman presented with minimal asymmetry. Her right side was short and wide relative to her left side, which had slightly greater midface height and was narrower. She has severe malar descent bilaterally and significant jowl formation, which is uncommon in her age group. She demonstrated an overall square facial shape. Her operative plan included an individualized component face lift with an open neck lift (platysmaplasty). The face lift technique involved limited skin

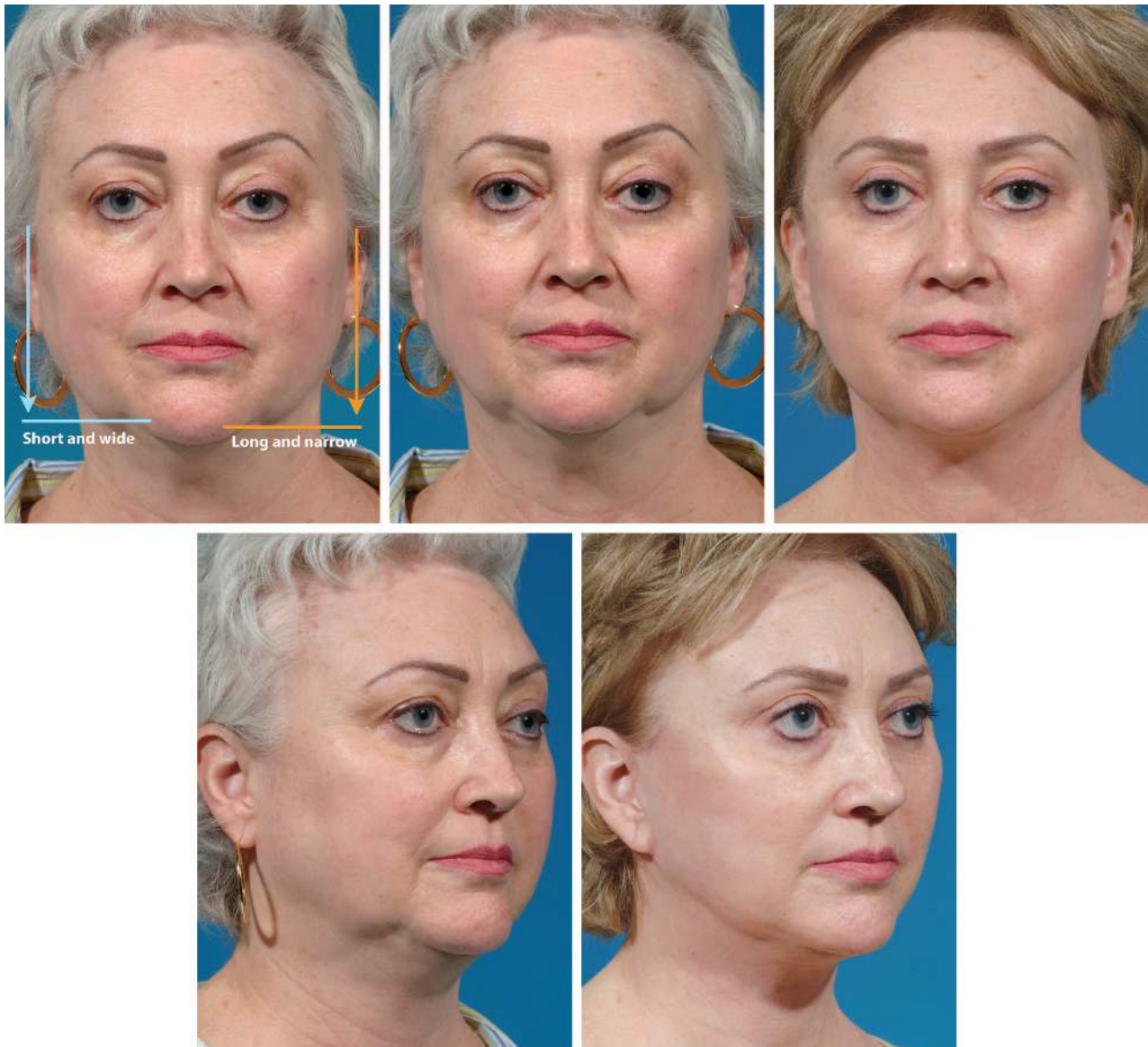

Fig. 10. Case 2. Preoperative and 1-year postoperative views of a 56-year-old patient with overall facial fullness and moderate asymmetry.

undermining on the right and more extended undermining on the left. SMAS-stacking was performed bilaterally to balance the lower-third width with the midface width. Horizontally oriented SMAS-stacking was used to allow a vertical lift on the right, and more obliquely positioned stacking was used on the left to redistribute her lower-third soft tissue more evenly between the two sides. Her square jawline was balanced with her midface to produce a more oval facial shape. Other procedures included upper blepharoplasty, laser resurfacing of the lower eyelids, and hyaluronic acid augmentation of the upper and lower vermillion (Fig. 11).

F11

Case 4

The patient in case 4 was a 48-year-old woman with severe facial asymmetry. Her right side was long and narrow relative to the left facial side, which was short and wide. She had less midface fullness on the right relative to the left side. Her orbital

volume was also greater on the right, corresponding to the longer side. Overall, she demonstrated a square facial contour with moderate overall facial fullness. Her operative plan included an individualized component face lift, an open neck lift (platysmaplasty), and fat augmentation to the medial nasolabial fat compartments and her marionette/commissure regions. For the individualized component face lift technique, extended undermining was done on her right side compared with her left. SMAS-stacking was performed on the right side, with additional “spot” imbrication of tissue to create more right-sided malar fullness. SMAS-stacking was also performed on left side but with smaller SMAS purchase, combined with some SMAS trimming. SMAS shaping was oriented horizontally on the left facial side for a vertical lift. Oblique SMAS-stacking (parallel to the nasolabial fold) was done on the right side to produce proper midface width and create contour balance between the two facial sides. Other procedures included quad-blepharoplasty,

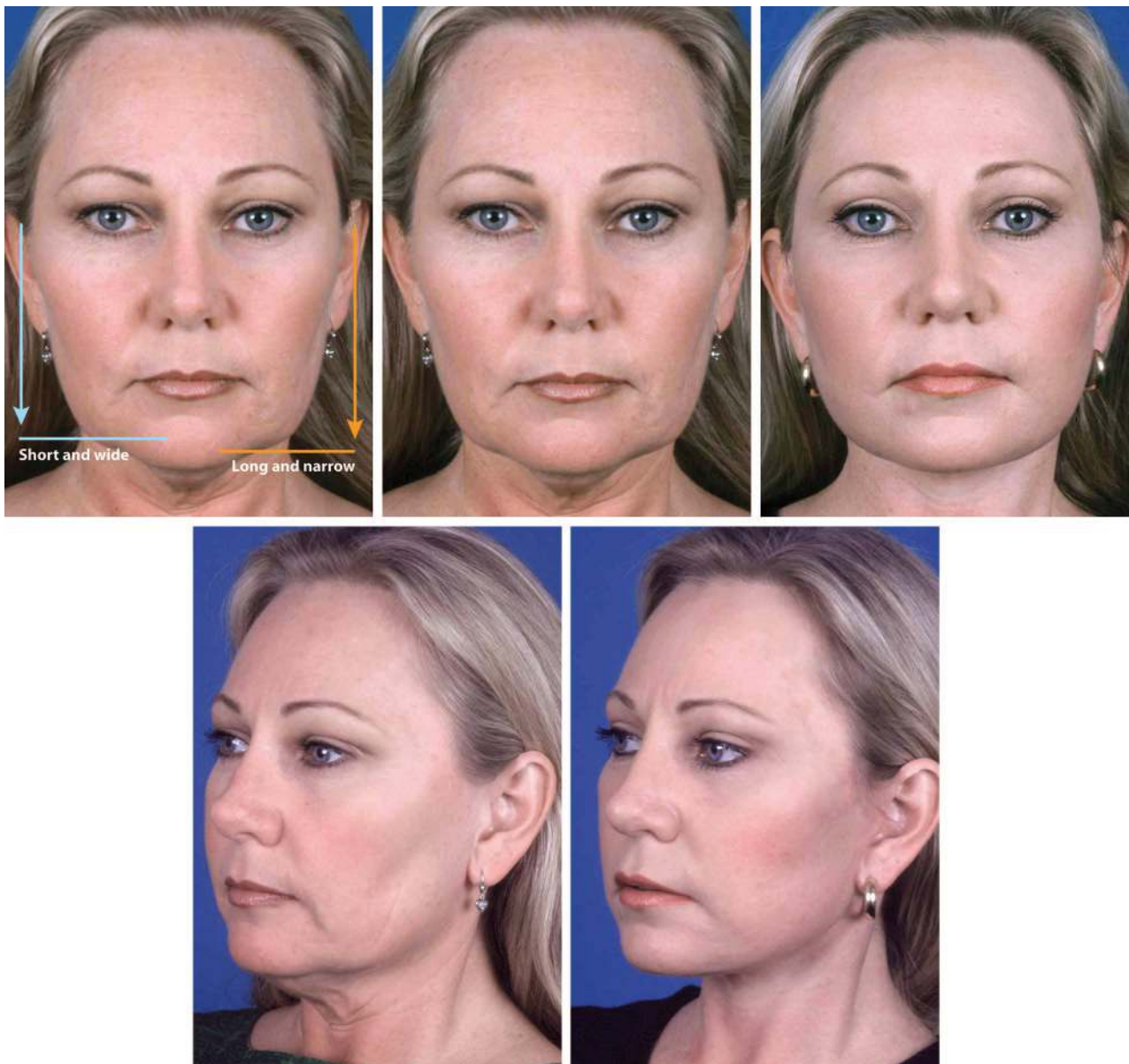

Fig. 11. Case 3. Preoperative and 1-year postoperative views of a 44-year-old patient with minimal asymmetry.

brow lift, and a 35 percent trichloroacetic acid full-face chemical peel (Figs. 12 through 15).

F12-15

DISCUSSION

In the modern era of facial rejuvenation, there exists a paradox in which patients have higher expectations and are more critical and in-

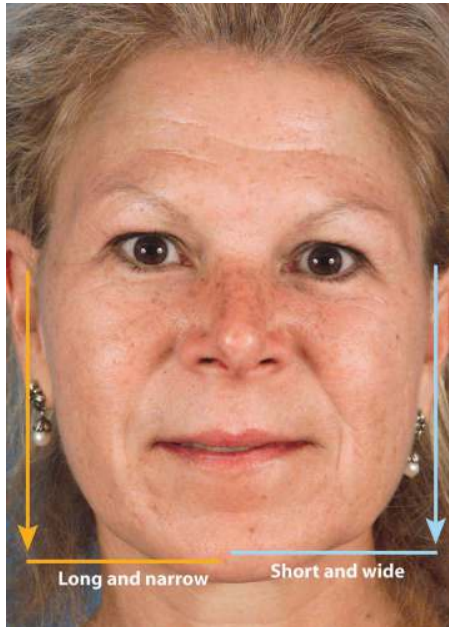

Fig. 12. Case 4. Preoperative appearance of a 48-year-old patient with severe facial asymmetry.

formed (often misinformed), but simultaneously demand as little “down time” as possible. Techniques that center on SMAS-ectomy⁶ and SMAS plication/imbrication^{1,10,12-14,16,18,19} with wide skin undermining obviate the need for extended sub-SMAS dissection and can still provide excellent outcomes.^{14,16,18,19,28} Furthermore, face lift techniques that undermine and elevate the SMAS layer are limited by the integrity of the SMAS, which can be attenuated medially. A further testament to this conundrum is the conversion to SMAS-ectomy or SMAS plication/imbrication techniques by sub-SMAS surgeons in secondary cases when the SMAS is thin and insubstantial.

A relatively simple, safe, yet highly effective method to partially counteract or correct facial aging is facial soft-tissue augmentation of selective fat compartments. Advanced methods of facial rejuvenation involve redistribution of the soft tissues to restore facial shape and contour to a more balanced, youthful state. This often requires some form of fat augmentation. The recent anatomical delineation of specific facial fat compartments now allows for more selective augmentation techniques to accompany the authors' face lift techniques.

Furthermore, to effectively alter facial shape, a system that reliably evaluates facial shape and guides the precise surgical technique is needed, similar to established methods of preoperative planning in rhinoplasty.^{22,23} Gonzales-Ulloa,³⁹

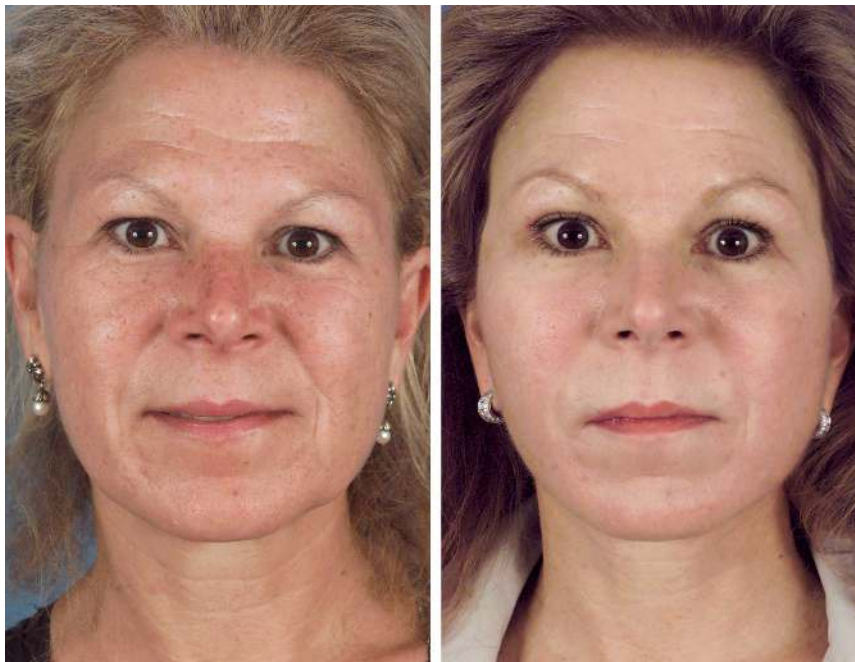

Fig. 13. Case 4. Preoperative and 1-year postoperative views of the patient shown in Figure 16.

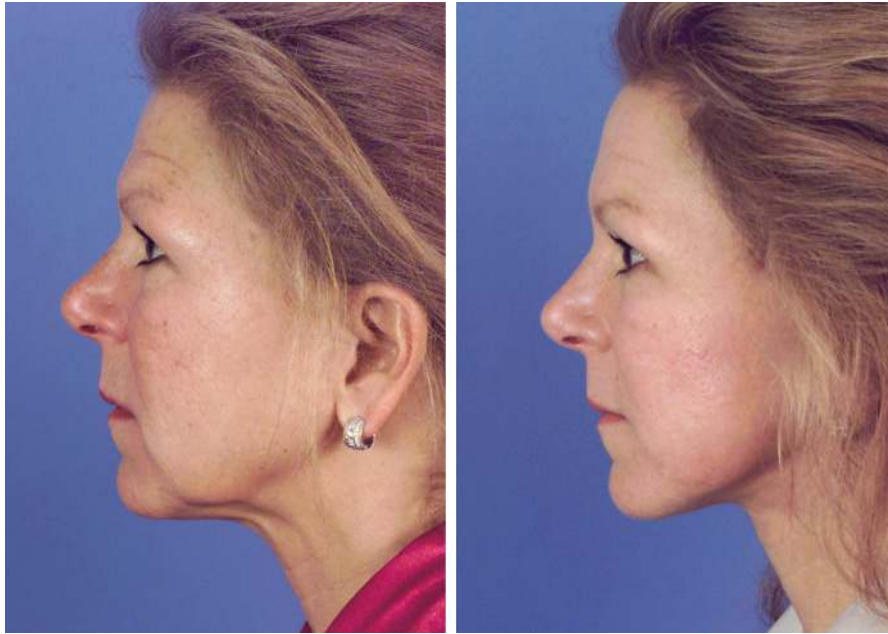

Fig. 14. Case 4. Additional views of the patient shown in Figures 16 and 17.

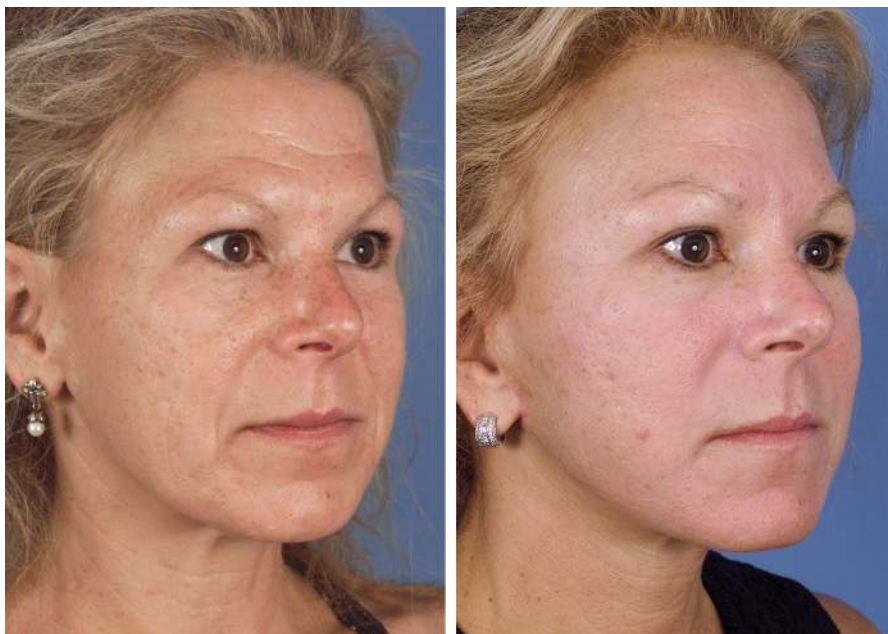

Fig. 15. Case 4. Additional preoperative and postoperative views.

Pitanguy,¹⁰ Furnas,⁴⁰ Hoefflin,¹¹ and Little⁴¹ have all described elegant and elaborate methods to analyze the face, but a versatile, yet simple, system that can be applied to different face lift techniques may prove more useful. We have provided a simple and reproducible system for preoperative facial analysis based on midface length, midface width, and the degree of facial asymmetry. Although the

asymmetry itself is not the primary factor in face lift technique decision-making, it helps direct the systematic analysis of overall facial shape.

Recently, Stuzin⁹ emphasized the importance of preoperative assessment of face lift patients and the concept of “facial shaping” rather than “face lifting.” The concept of simply lifting and tightening the SMAS, skin, and/or subcutaneous tissue

is flawed. We are now entering an era in which individualized reestablishment of youthful facial contour is attainable. Plication techniques are not new and have been well described by Aufricht,¹² Robbins et al.,¹ Baker,⁶ Ansari,¹⁶ and Saylan¹³ and widely popularized by Tonnard and Verpaele.¹⁴ The popularity of these techniques stems from their reproducibility, simplicity, and patient satisfaction.^{1,10,14,18} Combining these techniques with fat compartment augmentation may further improve their power and longevity. The authors strongly believe that fat augmentation should be a routine component of any modern face lift technique.

Through the works of Pessa,^{32,33} Ricketts,⁴² and others,³⁴ it has become clear that aesthetics, whether in nature or in the face, is a relationship between curves and shapes. Unfortunately, the changes that occur with facial aging are not fully understood but may involve a complicated multi-dimensional interaction between the underlying bony changes,³²⁻³⁴ skin/soft-tissue position (facial fat descent and/or deflation),^{7,4} selective fat compartment deflation,^{9,20,24,35} and alterations in the associated support ligaments and septi.^{20,21,28-30} Recently, Lambros³⁵ showed that true descent of soft tissues does not seem to be a major component of midface and periorbital aging. He revealed that the lid-cheek junction does not “descend” with age. With recent evidence of the fat compartments of the face, the concepts of soft-tissue deflation and formation of separations between the fat compartments seem to contribute more to the aged facial appearance.

In general terms, as facial fat deflates, there is less volume distributed throughout the face, particularly in areas that signify youth and beauty (i.e., the midface). This phenomenon presents as a loss of fullness in the malar region and an increase in soft-tissue volume in the submalar and mandibular regions, resulting in a loss of the angular contours of the face, which produces a more round or square facial shape. It is important to augment the weaker, less full midface with fat (along with SMAS-stacking) to further enhance the contour that is achieved through differential SMAS shaping. The authors (R.J.R., A.G., J.A.L.) now utilize fat augmentation to the malar, nasolabial, and oral commissure/marionette areas as a routine adjunct to rhytidectomy. The recent discovery of the facial fat compartments has improved the selectivity by which this fat augmentation is performed.²⁰

CONCLUSIONS

Individualizing face lift techniques through preoperative analysis is now as important in facial

rejuvenation as it has been in rhinoplasty. Varying how the SMAS is shaped according to preoperative evaluation can improve the predictability in face lift results. Recent adoption of individual fat compartment augmentation techniques provides further selectivity and precision in comprehensive facial rejuvenation. Rohrich and Pessa's²⁰ recent anatomical study on the facial fat compartments improves our understanding of the etiology of facial shape and may hold important clues regarding the discriminatory process of facial aging. In theory, facial aging may be characterized, in part, by how specific fat compartments age (deflate) differently in one individual versus another. Through continued anatomical research and repeated scrutiny of outdated concepts, the public's perception of facial rejuvenation will also improve as our aesthetic results continue to become more refined.

Rod J. Rohrich, M.D.

Department of Plastic Surgery
University of Texas Southwestern Medical Center
1801 Inwood Road
Dallas, Texas 75390-9132
rod.rohrich@utsouthwestern.edu

REFERENCES

1. Robbins LB, Brothers DB, Marshal DM. Anterior SMAS plication for the treatment of prominent nasomandibular folds and restoration of normal cheek contour. *Plast Reconstr Surg.* 1995;96:1279.
2. Skoog T. *Plastic Surgery: New Methods and Refinements.* Philadelphia: WB Saunders; 1974:302-330.
3. Ristow B. Milestones in the evolution of facelift techniques. In: JC Grotting, ed. *Reoperative Aesthetic and Reconstructive Plastic Surgery.* St. Louis: Quality Medical Publishing; 2007:219.
4. Hamra ST. The composite rhytidectomy. *Plast Reconstr Surg.* 1992;90:1.
5. Barton FE Jr. *Rhytidectomy and the nasolabial fold.* *Plast Reconstr Surg.* 1992;90:601.
6. Baker DC. Lateral SMASectomy. *Plast Reconstr Surg.* 1997; 100:509.
7. Owsley JQ. SMAS-platysma face lift. *Plast Reconstr Surg.* 1983; 71:573.
8. Connell BF, Semlacher RA. Contemporary deep layer facial rejuvenation. *Plast Reconstr Surg.* 1997;100:1513.
9. Stuzin J. Restoring facial shape in face lifting: The role of skeletal support in facial analysis and midface soft-tissue repositioning. *Plast Reconstr Surg.* 2007;119:362.
10. Pitanguy I. Facial cosmetic surgery: A 30-year perspective. *Plast Reconstr Surg.* 2000;105:1517.
11. Hoefflin SM. The extended supraplatysmal plane face lift. *Plast Reconstr Surg.* 1998;102:2513.
12. Aufricht G. Surgery for excess skin of the face and neck. In: *Transactions of the Second Congress of the International Society of Plastic Surgeons.* Baltimore: Williams & Wilkins; 1960:495.
13. Saylan Z. Purse string-formed plication of the SMAS with fixation to the zygomatic bone. *Plast Reconstr Surg.* 2002;110:667.
14. Tonnard P, Verpaele A. 300 MACS-lift short scar rhytidectomies: Analysis of results and complications. *Eur J Plast Surg.* 2005;28:198.

15. Stuzin J, Baker TJ, Baker TM. Refinements in face lifting: Enhanced facial contour using vicryl mesh incorporated into SMAS fixation. *Plast Reconstr Surg.* 2000;105:290.
16. Ansari P. S-lift: A sensational method of face-lift. Paper presented at: 25th Annual Meeting of the American Society for Aesthetic Plastic Surgery; May 15, 1992; Los Angeles, Calif.,
17. Massiha H. Short-scar face lift with extended SMAS plasty dissection and lifting and limited skin undermining. *Plast Reconstr Surg.* 2003;112:663.
18. Webster RC, Smith RC, Karolow WM, Papsidero MJ, Smith KF. Comparison of SMAS plication with SMAS imbrication in face lifting. *Laryngoscope* 1982;92:901.
19. Webster RC, Smith RC, Smith KF. Face lift: Part 3. Plication of the superficial musculoaponeurotic system. *Head Neck Surg.* 1983;6:696.
20. Rohrich RJ, Pessa J. The fat compartments of the face: Anatomy and clinical implications for cosmetic surgery. *Plast Reconstr Surg.* 2007;119:2219.
21. Ghavami A, Pessa J, Janis JE, Khosla R, Reece EM, Rohrich RJ. The orbicularis retaining ligament of the medial orbit: Closing the circle. *Plast Reconstr Surg.* 2008;121:994.
22. Guyuron B. Precision rhinoplasty. Part II: Prediction. *Plast Reconstr Surg.* 1988;81:500.
23. Byrd HS, Hobar PC. Rhinoplasty: A practical guide for surgical planning. *Plast Reconstr Surg.* 1993;91:642.
24. Lambros V. *Personal communication*, 1999.
25. Lambros V. Fat contouring in the face and neck. *Clin Plast Surg.* 1992;19:401.
26. Tessier P. Le lifting facial sous-perioste. *Ann Chir Plast Esthet.* 1989;34:193.
27. Mitz V, Peyronie M. The superficial musculoaponeurotic system (SMAS) in the parotid and cheek area. *Plast Reconstr Surg.* 1976;58:80.
28. Furnas DW. The retaining ligaments of the cheek. *Plast Reconstr Surg.* 1989;83:11.
29. Stuzin JM, Baker TJ, Gordon HL. The relationship of the superficial and deep facial fascias: Relevance to rhytidectomy and aging. *Plast Reconstr Surg.* 1992;89:441.
30. Mendelson B. Surgery of the superficial musculoaponeurotic system: Principles of release, vectors, and fixation. *Plast Reconstr Surg.* 2001;107:1545.
31. Moss CJ, Mendelson BC, Taylor GI. Surgical anatomy of the ligamentous attachments in the temple and periorbital regions. *Plast Reconstr Surg.* 2000;105:1475.
32. Pessa JE. An algorithm of facial aging: Verification of Lambro's theory by three-dimensional stereolithography, with reference to the pathogenesis of midfacial aging, scleral show, and the lateral suborbital through deformity. *Plast Reconstr Surg.* 2000;106:479.
33. Pessa JE. Concertina effect and facial aging: Nonlinear aspects of youthful skeletal remodeling, and why, perhaps, infants have jowls. *Plast Reconstr Surg.* 1999;103:635.
34. Zadoo VP, Pessa JE. Biological arches and changes to the curvilinear form of the aging maxilla. *Plast Reconstr Surg.* 2000;106:460.
35. Lambros V. Observations on periorbital and midface aging. *Plast Reconstr Surg.* 2007;120:1367.
36. Yousif NJ, Gosain A, Sanger JR, Larson DL, Matloub HS. The nasolabial fold: A photogrammetric analysis. *Plast Reconstr Surg.* 1994;36:239.
37. Barton FE Jr. Restoring facial shape in face lifting: The role of skeletal support in facial analysis and midface soft-tissue repositioning (Discussion). *Plast Reconstr Surg.* 2007;119:362.
38. Ivy EJ, Lorenc ZP, Aston SJ. Is there a difference? A prospective study comparing lateral and standard SMAS face lifts with extended SMAS and composite rhytidectomies. *Plast Reconstr Surg.* 1996;98:1135.
39. Gonzalez-Ulloa M. Quantitative principles in cosmetic surgery of the face (profileplasty). *Plast Reconstr Surg.* 1962;29:186.
40. Furnas DW. Anthropometric landmarks for precision planning in rhytidectomy. *Clin Plast Surg.* 1987;14:639.
41. Little JW. Volumetric perceptions in midfacial aging with altered priorities for rejuvenation. *Plast Reconstr Surg.* 2000;105:252.
42. Ricketts RM. The biological significance of the divine proportion and the Fibonacci series. *Am J Orthod.* 1982;81:351.

AUTHOR QUERIES

AUTHOR PLEASE ANSWER ALL QUERIES

1

- AQ1: AUTHOR—Per Journal style, the abstract should not exceed 250 words. The current abstract was reduced from 377 words to 263 words. Correct as edited? If not, please revise as needed, keeping in mind Journal word limits and that the Journal prefers not to use abbreviations and acronyms.
- AQ2: AUTHOR—Legend to Figure 1: ICR was spelled out as individualized component face lift. As meant? If not, please supply the correct expansion.
- AQ3: AUTHOR—Ref. 38 was not cited in the original text, so a citation was added at the end of the Patient Evaluation and Aesthetic Goals section, in brackets, for programmatic reasons only. Please cite ref. 38 in text where wanted, in numerical order per Journal style to avoid extensive renumbering.
- AQ4: AUTHOR—Facial Length section, para. 2, last sentence: Correct as edited? “Occasionally, the long facial side can be the wider side is treated” was changed to “Occasionally, the long facial side can be the wider side if it is treated.” Please advise/revise as needed.
- AQ5: AUTHOR—Since there was no text in the main article to describe the patient in Case 1, and since the legends for figures 7, 8, and 9 were identical, the legend was moved to the main text and the legends were shortened. Correct as edited? If not, please supply additional text for the legends. The same thing was done for the remaining cases and figures.
- AQ6: AUTHOR—Case 2 section: Last sentence (re: other procedures) correct as edited? If not, please revise as needed.
-