

The Aesthetic Earlobe: Classification of Lobule Ptosis on the Basis of a Survey of North American Caucasians

Arian Mowlavi, M.D., D. Garth Meldrum, M.D., Bradon J. Wilhelmi, M.D., Ashkan Ghavami, M.D., and Elvin G. Zook, M.D.

Springfield, Ill.

North American Caucasian male subjects ($n = 59$) and female subjects ($n = 72$) were surveyed, to investigate earlobe height preferences that could serve as guidelines for aesthetic earlobe surgical procedures and reconstructions. Subjects were asked to rank their preferences for variously shaped earlobes in life-size-scaled sketched male and female profiles. Earlobe heights were varied on the basis of previously established anatomical landmarks, including the intertragal notch, the most caudal anterior attachment of the earlobe to the cheek skin (the otobasion inferius), and the most caudal extension of the earlobe-free margin (the subaurale). While the intertragal notch-to-otobasion inferius distance (range, 5 to 20 mm) and otobasion inferius-to-subaurale distance (range, 0 to 20 mm) varied, all other facial and ear anthropometric measurements were held constant. Each of the rank orders for the female and male facial profiles completed by the female and male subjects demonstrated statistical significance, as determined by one-way analysis of variance analysis of ranks ($p < 0.001$ for all four groups). No difference was noted between the two sexes' rank orders for either sex ($p > 0.05$). Therefore, analysis of the combined male and female preferences for each sex was completed with one-way analysis of variance analysis of ranks ($p < 0.001$ and $p < 0.001$) and a post hoc Dunn's test, to delineate significant preference differences between subgroups with respect to the intertragal notch-to-otobasion inferius and otobasion inferius-to-subaurale distances. Both female and male earlobe intertragal notch-to-otobasion inferius distances were preferred at either 5, 10, or 15 mm, more so than at 20 mm ($p < 0.05$ for all female and male comparisons). Furthermore, both female and male earlobe otobasion inferius-to-subaurale distances were preferred, in descending order, at 5 mm $>$ 10 mm $>$ 0 mm $>$ 15 mm $>$ 20 mm ($p < 0.05$ for all female and male comparisons). On the basis of the findings of this survey, the first classification of earlobe ptosis (based on otobasion inferius-to-subaurale distances), as well as a criterion for earlobe pseudoptosis (intertragal notch-to-otobasion inferius distance of greater than 15 mm), is presented. These findings suggest a role for independent assessment of the lobule length with respect to its anteriorly

attached cephalad component (intertragal notch-to-otobasion inferius distance) and its free-margin caudal component (otobasion inferius-to-subaurale distance). (*Plast. Reconstr. Surg.* 112: 266, 2003.)

Although guidelines for ear size and orientation have been studied, minimal attention has been directed to the ear lobule. Lobule height has been suggested to span 25 percent of the ear length.¹ Ear length was described by Farkas² as the medial longitudinal distance from the highest point on the free margin of the auricle (the supraaurale) to the lowest point on the free margin of the ear lobe (the subaurale). Analyses of 100 healthy adults and 50 children demonstrated that the ear height and width measured 6.5 and 3.5 cm, respectively. Earlobe heights, as defined by the antitragus-to-subaurale distance, were subsequently determined to range between 1.5 and 2.0 cm.³

Earlobe ptosis, as an isolated condition in facial aging, has not been defined. Aging deformity of the earlobe has been discussed only in association with rhytidectomy procedures. As early as 1972, Loeb⁴ recognized the potential need for earlobe reduction, as a supplement to rhytidectomy, for certain individuals. He described the distance from the intertragal notch to the anterior caudal implantation of the earlobe (the otobasion inferius) as a parameter requiring evaluation. In his observations, he noted a range of intertragal notch-to-otobasion inferius distances of 1 to 2.5 cm, and

From the Plastic Surgery Institute, Southern Illinois University, School of Medicine.

DOI: 10.1097/01.PRS.0000066368.07829.9B

he advocated correction when this distance exceeded 2.0 cm preoperatively. He presented a surgical design for earlobe reduction that he used for 271 of 667 face lifts, with satisfactory results.⁴ Unfortunately, that study did not take into account the entire lobule height, neglecting the most caudal segment of the lobule (from the otobasion inferius to the subaurale).

A more thorough assessment of earlobe height is possible by taking into account the entire lobule length, as designated by its most cephalic component, the intertragal notch-to-otobasion inferius distance described by Loeb,⁴ and also by its most caudal margin, the otobasion inferius-to-subaurale distance (Fig. 1). We completed a survey of specific lobule length preferences and devised a classification system for earlobe ptosis based on the aforementioned parameters, which could serve as a guide for aesthetic earlobe surgical reduction and reconstruction.

PATIENTS AND METHODS

North American Caucasian female subjects ($n = 76$) and male subjects ($n = 59$) were surveyed with respect to their preferred earlobe shape. Subjects were asked to rank, in order of most desired to least desired, ear shapes in life-size-scaled male and female

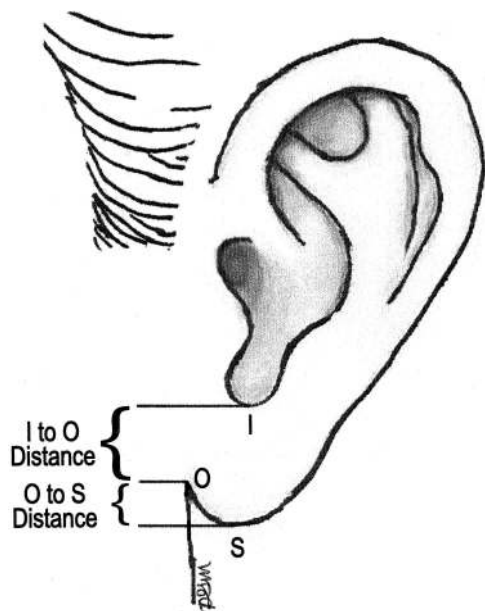


FIG. 1. Anatomical landmarks of the intertragal notch (I), otobasion inferius (O), and subaurale (S). Earlobe height parameters were defined with respect to the attached cephalic component (intertragal notch-to-otobasion inferius distance) and the free-margin caudal component (otobasion inferius-to-subaurale distance).

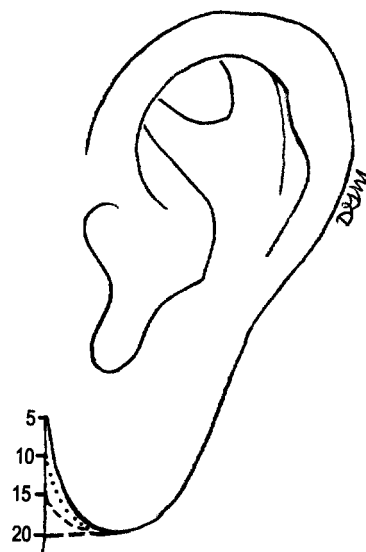


FIG. 2. Range of intertragal notch-to-otobasion inferius distances assessed (5 to 20 mm). Evaluators were asked to rank, in order of most desired to least desired, ear shapes in life-size female and male sketched profiles in which the intertragal notch-to-otobasion inferius distance was altered.

sketched profiles in which the intertragal notch-to-otobasion inferius distance was altered from 5 to 20 mm (Fig. 2) and the otobasion inferius-to-subaurale distance was varied from 0 to 20 mm (Fig. 3). Distances were measured in the vertical plane perpendicular to the Frankfurt horizontal plane and passing through the intertragal notch. All other facial and ear anthropometric measurements were held constant and were in accordance with previously published reports of aesthetically ideal North American Caucasian female and male faces.^{5,6} Specifically, the ear longitudinal length was set at 65 mm and the longitudinal axis was drawn 15 degrees vertical to the nasal bridge axis.^{5,6}

Surveys with completion of all rank orders were included in the final assessment. Using the intertragal notch-to-subaurale distance as the lobule height, we designated the attached cephalic component as the intertragal notch-to-otobasion inferius distance and the free-margin caudal component as the otobasion inferius-to-subaurale distance. The otobasion inferius has been designated the most caudal point of attachment of the earlobe to the cheek skin.⁷

Rank averages and orders were independently compiled for each of the female and male subjects, with respect to the faces of each sex. One-way analysis of variance analysis of ranks and post hoc Dunn's tests were used to

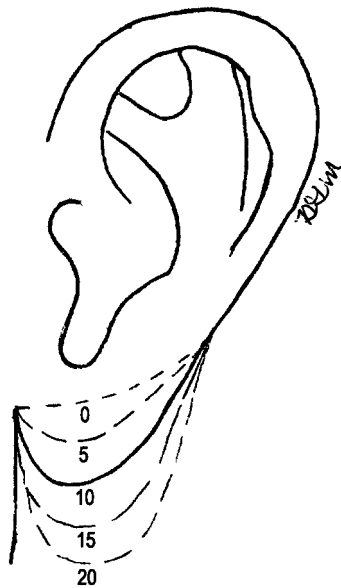


FIG. 3. Range of otobasion inferius-to-subaurale distances assessed (0 to 20 mm). Evaluators were asked to rank, in order of most desired to least desired, ear shapes in life-size female and male sketched profiles in which the otobasion inferius-to-subaurale distance was altered.

detect any significant trends in rank orders and to delineate specific intertragal notch-to-otobasion inferius and otobasion inferius-to-subaurale distance preferences.

RESULTS

Rank averages and order preferences for both the female and male faces demonstrated significant preference differences among the varied intertragal notch-to-otobasion inferius and otobasion inferius-to-subaurale distances ($p < 0.001$ for all four groups) (Figs. 4 and 5). No difference was noted between the two sexes' rank orders for either sex ($p > 0.05$). Therefore, analysis of the combined male and female sketched lobule preferences for each sex was completed with one-way analysis of variance ($p < 0.001$ for each sex profile) and a post hoc Dunn's test, to delineate significant differences with respect to the intertragal notch-to-otobasion inferius and otobasion inferius-to-subaurale distances. Both female and male earlobe intertragal notch-to-otobasion inferius distances were preferred at either 5, 10, or 15 mm more so than at 20 mm ($p < 0.05$ for all male and female comparisons). Both female and male earlobe otobasion inferius-to-subaurale distance preferences were ordered, from most to least desired, at 5 mm $>$ 10 mm $>$ 0 mm $>$ 15 mm $>$ 20 mm ($p < 0.05$ for all male and female comparisons).

DISCUSSION

In surveys of North American Caucasians, significant preferences were demonstrated for intertragal notch-to-otobasion inferius and otobasion inferius-to-subaurale distances in the female and male earlobe profiles (Figs. 4 and 5). It is apparent that, in assessments of the entire earlobe height (intertragal notch-to-subaurale distance), the otobasion inferius-to-subaurale component was more stringently evaluated. A definite preference order for the otobasion inferius-to-subaurale component of 5 mm $>$ 10 mm $>$ 0 mm $>$ 15 mm $>$ 20 mm was observed irrespective of the sex of the subject or evaluator. In contrast, the intertragal notch-to-otobasion inferius distance was more leniently evaluated, with a tolerance for distances of 5, 10, and 15 mm. Only the intertragal notch-to-otobasion inferius distance of greater than 15 mm was found to be unappealing, for both female and male faces.

With consideration of these preferences, a classification system for earlobe ptosis based on the otobasion inferius-to-subaurale distance was devised (Table I). The ideal earlobe ptosis (intertragal notch-to-subaurale distance of 1 to 5 mm) was designated grade I, and a lack of ptosis (intertragal notch-to-subaurale distance of 0 mm) was designated grade 0. Undesired ptosis grades ranged from grade II through grade V, with intertragal notch-to-subaurale distances of 6 to 10, 11 to 15, 16 to 20, and more than 20 mm, respectively (Table I). Because intertragal notch-to-otobasion inferius distances were tolerated up to 15 mm, we designated pseudoptosis as a cephalad lobule height component with an intertragal notch-to-otobasion inferius distance of greater than 15 mm.

This classification system for earlobe ptosis may allow a more precise, quantified approach to aesthetic earlobe reduction or reconstruction. On the basis of preferences identified in this survey, reduction procedures may be indicated for earlobe grades II through V. In contrast, earlobe augmentation may be desired for lobules with grade 0 ptosis, with local tissue transfer using a banner flap from the preauricular and mandibular areas of the cheek.⁸ Finally, surgical earlobe alteration may also be indicated for earlobes meeting the criterion for pseudoptosis (i.e., an intertragal notch-to-otobasion inferius distance of greater than 15 mm).

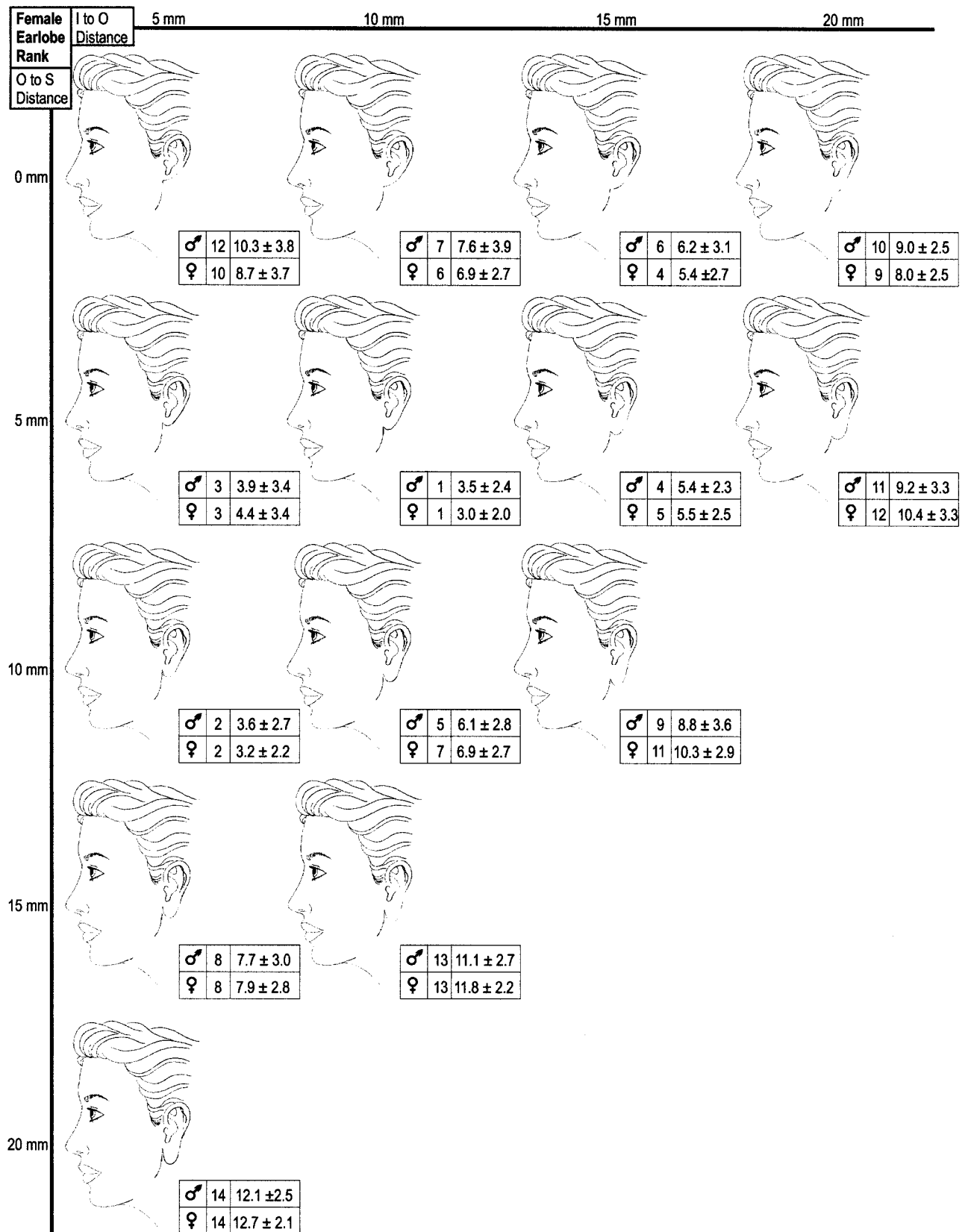


FIG. 4. Illustrations of female ear shapes and rank averages and orders of male and female preferences. The intertragal notch-to-otobasion inferius (*I to O*) and otobasion inferius-to-subaurale (*O to S*) distance preferences were tabulated from surveys completed by North American Caucasian male and female subjects. The selections made by the female and male evaluators demonstrated statistical significance within each of the rank orders, as assessed by one-way analysis of variance ($p < 0.001$).

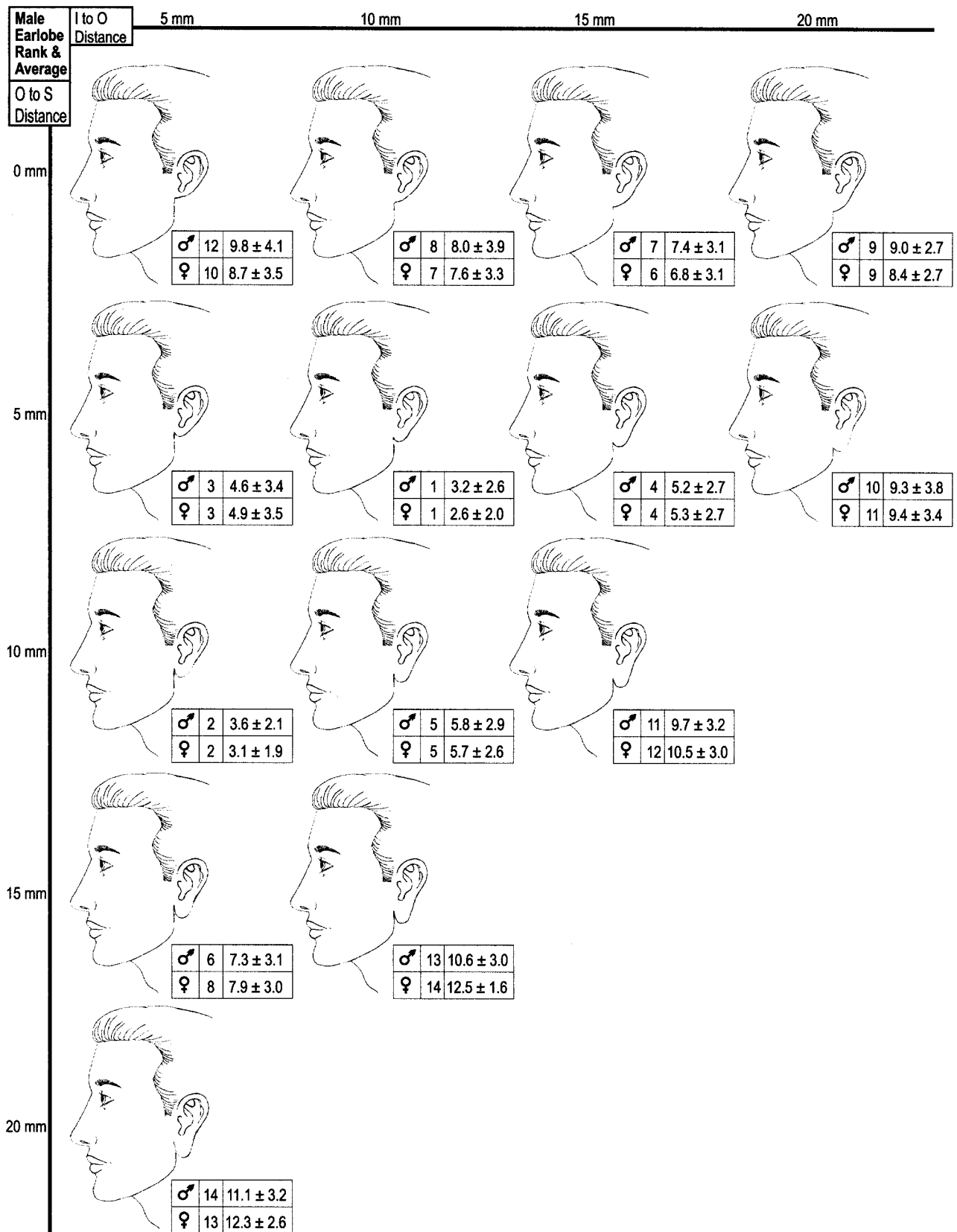


FIG. 5. Illustrations of male ear shapes and rank averages and orders of male and female preferences. The intertragal notch-to-otobasion inferius (*I to O*) and otobasion inferius-to-subaurale (*O to S*) distance preferences were tabulated from surveys completed by North American Caucasian male and female subjects. The selections made by the female and male evaluators demonstrated statistical significance within each of the rank orders, as assessed by one-way analysis of variance ($p < 0.001$).

TABLE I

Classification of Earlobe Ptosis on the Basis of an Analysis of Preferred Otobasion Inferius-to-Subaurale Distances in Male and Female Faces

Ptosis Grade	Otobasion Inferius-to-Subaurale Distance (mm)
0	0
I	1-5
II	6-10
III	11-15
IV	16-20
V	>20

With consideration of both the intertragal notch-to-otobasion inferius and otobasion inferius-to-subaurale distances, more accurate surgical techniques may be developed to independently treat pseudoptosis and/or ptosis defects. To date, several techniques for earlobe reduction have been described, involving excisions of the anterior skin^{4,9,10} and excisions of the posterior skin.¹¹⁻¹³ Unfortunately, these surgical techniques do not specifically address the differential effects on the intertragal notch-to-otobasion inferius and otobasion inferius-to-subaurale distances, and the surgical results have not been quantified. With the use of a quantitative parameter, as presented in this lobule classification system, it should be possible to accurately define lobule excess and evaluate postoperative outcomes.

McKinney et al.¹⁴ studied 100 predominantly Caucasian subjects (age range, 19 to 79 years; average age, 39 years; equal numbers of female and male subjects) and observed an average lobule height of 18 mm (range, 13 to 25 mm), as determined on the basis of the intertragal notch-to-subaurale distance. The average ear length of 65 mm (range, 56 to 81 mm) resulted in an average lobule length ratio (ratio of the length of the lobule to that of the long axis of the ear) of 28 percent (range, 23 to 34 percent). Those authors recommended that the lobule height be corrected when it exceeded 33 percent of the total ear length. They recommended a simple anterior staircase excision of the lobule, as a supplementary procedure during rhytidectomy, for such ears.¹⁴ That study failed to delineate the contribution of the two earlobe components, the attached cephalad segment (intertragal notch-to-otobasion inferius) as well as the free caudal segment (otobasion inferius-to-subaurale).

An acquired deformity resulting from aging may involve elongation or ptosis of the earlobe, which has been attributed to loss of elastic

fibers and gravitational pull.¹⁵ To date, there have been few reports quantifying lobule elongation (i.e., ptosis).^{4,14} This is most evident in the recommendation by Tipton¹³ for clinicians to arrive at an agreement with their patients regarding the desired lobule shape before surgical manipulation. Although such an approach is worthwhile, it emphasizes the lack of an earlobe ptosis designation system. On the basis of the findings of our study, we describe a classification system for earlobe ptosis that designates grades 0 through V, as determined directly from significant differences in earlobe preferences. Furthermore, we have identified a criterion for earlobe pseudoptosis based on preference differences for the attached cephalad component of lobule height (intertragal notch-to-otobasion inferius distance). The designation of pseudoptosis should further facilitate more accurate diagnosis and correction of earlobe elongation. In summary, this ptosis classification system and pseudoptosis designation could help guide plastic surgeons during aesthetic earlobe surgical procedures and reconstruction.

Bradon J. Wilhelmi, M.D.

The Plastic Surgery Institute

Southern Illinois University, School of Medicine

747 N. Rutledge

P.O. Box 19653

Springfield, Ill. 62794-9653

bwilhelmi@siu-med.edu

REFERENCES

1. McKinney, P., and Cunningham, B. L. *Aesthetic Facial Surgery*. New York: Churchill Livingstone, 2002. P. 222.
2. Farkas, L. G. Appendix A-1. In *Anthropometry of the Head and Face*. New York: Raven, 1994. P. 374.
3. Rubin, L. R., Bromberg, B. E., Walden, R. H., and Adams, A. An anatomic approach to the obtrusive ear. *Plast. Reconstr. Surg.* 29: 360, 1962.
4. Loeb, R. Earlobe tailoring during facial rhytidoplasties. *Plast. Reconstr. Surg.* 49: 485, 1972.
5. Farkas, L. G. Anthropometry of the normal and defective ear. *Clin. Plast. Surg.* 17: 213, 1990.
6. Skiles, M. S., and Randall, P. The aesthetics of ear placement: An experimental study. *Plast. Reconstr. Surg.* 72: 133, 1983.
7. Martin, R., and Saller, R. *Lehrbuch der Anthropologie*, Vol. 1, 3rd Ed. Stuttgart: Fischer, 1957.
8. Tannir, D., and Leshin, B. Utility of a bilayered banner transposition flap in reconstruction of the lower third of the pinna. *Dermatol. Surg.* 26: 688, 2000.
9. Guerrero-Santos, J. Correction of hypertrophied earlobes in leprosy. *Plast. Reconstr. Surg.* 46: 381, 1970.
10. Lassus, C. Another technique for the reduction of the earlobe. *Aesthetic Plast. Surg.* 6: 43, 1982.

11. Enna, C. D., and Delgado, D. D. Surgical correction of common facial deformities due to leprosy. *Plast. Reconstr. Surg.* 42: 422, 1968.
12. Tanzer, R. C. Congenital deformities of the auricle. In J. M. Converse (Ed.), *Reconstructive Plastic Surgery*, 2nd Ed. Philadelphia: Saunders, 1977. P. 1719.
13. Tipton, J. B. A simple technique for reduction of the earlobe. *Plast. Reconstr. Surg.* 66: 630, 1980.
14. McKinney, P., Giese, S., and Placik, O. Management of the ear in rhytidectomy. *Plast. Reconstr. Surg.* 92: 858, 1993.
15. Constant, E. Reduction of hypertrophic earlobe. *Plast. Reconstr. Surg.* 64: 264, 1979.