

Tip Shaping in Primary Rhinoplasty: An Algorithmic Approach

Ashkan Ghavami, M.D.
Jeffrey E. Janis, M.D.
Cengiz Acikel, M.D.
Rod J. Rohrich, M.D.

Beverly Hills, Calif.; Dallas, Texas;
and Uskudar, Istanbul, Turkey

Background: Underprojection and lack of tip definition often coexist. Techniques that improve both nasal tip refinement and projection are closely interrelated, and an algorithmic approach can be developed to improve the predictability of the dynamic changes that occur. Use of nondestructive and nonpalpable techniques that enhance nasal tip shape are emphasized.

Methods: A retrospective review of primary rhinoplasty patients was undertaken to delineate the precise role of preoperative analysis, intraoperative evaluation, and execution of specific surgical techniques in creating nasal tip refinement and projection. Specific case studies are used to demonstrate the efficacy and predictability of these maneuvers.

Results: Successful tip refinement and projection depends on (1) proper preoperative analysis of the deformity; (2) a fundamental understanding of the intricate and dynamic relationships between tip-supporting structures that contribute to nasal tip shape and projection; and (3) execution of the operative plan using controlled, nondestructive, and predictable surgical techniques.

Conclusions: A simplified algorithmic approach to creating aesthetic nasal tip shape and projection in primary rhinoplasty has been established to aid the rhinoplasty surgeon in reducing the inherent unpredictability of combined techniques and improving long-term aesthetic outcomes. (*Plast. Reconstr. Surg.* 122: 1229, 2008.)

Attaining a well-defined and properly projecting nasal tip is a vital component for success in tip shaping and is predicated on a fundamental understanding of the anatomical components that provide nasal tip support and their influences on tip projection and shape (Table 1).¹⁻⁶

The length, width, strength, shape, and position of the lower lateral cartilages and the ligamentous attachments between these paired structures are critical in supporting the nasal tip.¹⁻⁶ The upper lateral cartilages, nasal septum, nasal base, and pyriform aperture provide additional stability and support to the nasal tip through their soft-tissue attachments.¹⁻¹¹

Preoperatively, an underprojecting nasal tip may be diagnosed as the primary nasal deformity or may accompany other nasofacial imbalances. Iatrogenic

loss of tip support may result from purposeful or unintended violation of critical tip-supporting structures.^{8,9} Maneuvers such as cephalic trimming of lower lateral cartilages, caudal septal resection, dorsal reduction, transfixion incisions, and alar base resections impact tip support and can cause a substantial reduction in tip projection.^{1,5,12-14} The open approach can also lead to diminished tip projection by virtue of disruption of skin and soft-tissue supports.²⁹

Historically, conventional destructive and irreversible tip-modification techniques such as cartilaginous resection, transection, morselization, and scoring have been replaced by nondestructive, reversible, incremental, and dynamic tip-suturing techniques.^{3,4,11-13,15-26} The popularity of visible/palpable cartilage grafts placed in a subcutaneous pocket underneath nasal skin has declined in recent years in favor of invisible/nonpalpable grafts placed within or underneath the cartilaginous framework.^{4,13-15,27,28}

From the Department of Plastic Surgery, University of Texas Southwestern Medical Center; the Department of Plastic and Reconstructive Surgery and Burn Unit, Gulhane Military Medical Academy, Haydarpasa Hospital; and Private Practice.

Received for publication January 6, 2007; accepted July 9, 2007.

Copyright ©2008 by the American Society of Plastic Surgeons

DOI: 10.1097/PRS.0b013e31817d5f7d

Disclosure: None of the authors received financial benefit from any commercial entity in support of this article.

Table 1. Factors that Determine Tip Projection

Length, width, and strength of the lower lateral cartilages
Length and stability of the medial crura
Suspensory ligament that spans the crura over the anterior septal angle of the upper and lower lateral cartilages
Fibrous connections between the upper and lower lateral cartilages
Abutment with the pyriform aperture
Anterior septal angle
Skin and soft-tissue thickness and availability

PREOPERATIVE ASSESSMENT AND PLANNING

The first step in the preoperative assessment lies in concomitant evaluation of the lip-chin complex.³⁰ Byrd and Hobar³¹ suggest establishing a nose-lip-chin plane with ideal chin projection (in women) defined as 3 mm posterior to a plumb line drawn perpendicular to the natural horizontal Frankfort plane (Fig. 1). The appearance of proper tip projection is dependent on this relationship,³⁰ as an underprojected chin will make the nasal tip seem overprojected and vice versa.

The next step is evaluation of the thickness and sebaceous character of the nasal skin. Men³² and certain ethnic subgroups such as those of African American,³³ Mediterranean, Hispanic,³⁴ and Middle Eastern^{35,36} descent tend to have thicker, more sebaceous skin that is less contractile and may camouflage the results of tip modification. Therefore, more aggressive maneuvers in

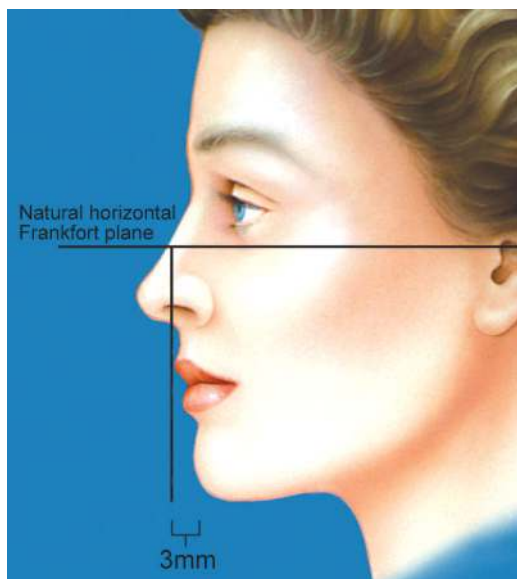


Fig. 1. Evaluation of nose-lip-chin balance relative to the natural horizontal Frankfort plane. [Reprinted from J. P. Gunter, R. J. Rohrich, and W. P. Adams, Jr. (Eds.), *Dallas Rhinoplasty: Nasal Surgery by the Masters*, 1st Ed. St. Louis: Quality Medical, 2007.]

these patients may be necessary to achieve the desired result.³³⁻³⁵ This needs to be balanced, however, to avoid creation of an iatrogenic “tension tip.”³⁷

Next, attention is turned toward proportional nasal analysis, which has been thoroughly described previously.^{38,39} Tip definition is best assessed on the frontal and basal views.^{40,41} The presence of domal asymmetry, tip dysmorphism (boxy or bulbous tip), degree of nostril show, columellar excess, caudal septal deviation, and a plunging (static) or hyperdynamic tip (animated) are noted. Animated views should be attained to diagnose depressor septi nasi hyperactivity resulting in hyperdynamic tip ptosis.⁴²

Tip projection on the lateral view is evaluated by determining the proportion of the tip that lies anterior to a vertical line drawn adjacent to the most projecting part of the upper lip. Fifty to 60 percent of the tip should lie anterior to this vertical line, and less than this is deemed tip underprojection. Proper tip projection can also be measured as 0.67 times the ideal nasal length³¹ (Fig. 2).

The nasolabial angle and alar-columellar relationship should also be evaluated on lateral view using previously established criteria.^{38,39} Maneuvers that increase tip projection will frequently affect the nasolabial and columellar-labial angles.

Nostril-tip proportion should be evaluated on the basal view. The ideal nostril-tip relationship should be approximately 2:1⁴⁰ (Fig. 3). An imbalance can produce either an illusory or true nostril-tip disproportion, with tip overprojection if the nostril is short⁴⁰ and an insufficient nasal tip if the nostril is long.⁴³

Management Algorithm and Operative Technique

Our algorithmic approach for tip refinement and increasing projection is outlined in Figure 4. Although tip sutures and other maneuvers in rhinoplasty can produce a multitude of dynamic changes, only those that pertain to nasal tip refinement and tip projection are described here (Table 2).

Intraoperative Analysis

Each of the elements responsible for tip support is analyzed individually after adequate exposure. The lateral crura are assessed for their degree of convexity/concavity, length/width dimensions, position, and symmetry. Analysis of the length and strength of the medial crura is critical for tip projection and definition. Medial crura that are long and stable are less likely to contribute to loss of tip projection postoperatively. Short and/or weak medial crura can lead to a loss of

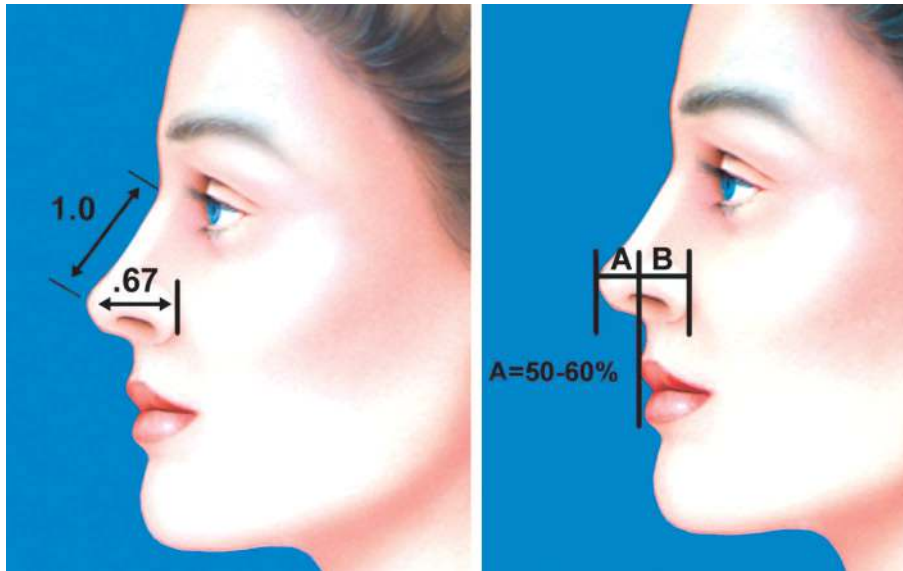


Fig. 2. Approximately 50 to 60 percent of the tip should project beyond the anteriormost projecting point of the upper lip, and/or projection should be 0.67 times the ideal nasal length. [Reprinted from J. P. Gunter, R. J. Rohrich, and W. P. Adams, Jr. (Eds.), *Dallas Rhinoplasty: Nasal Surgery by the Masters*, 1st Ed. St. Louis: Quality Medical, 2007.]

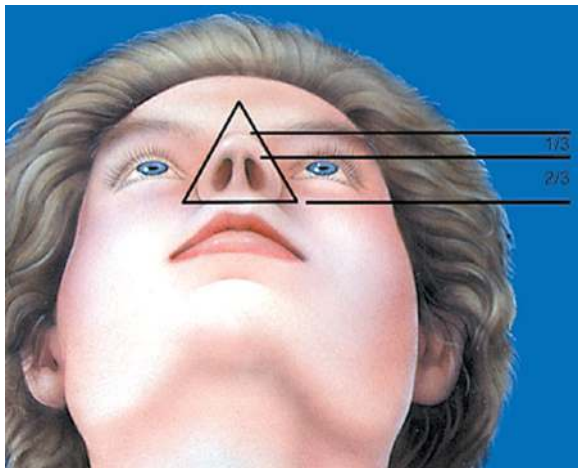


Fig. 3. The ideal nostril-tip relationship is 2:1. [Reprinted from J. P. Gunter, R. J. Rohrich, and W. P. Adams, Jr. (Eds.), *Dallas Rhinoplasty: Nasal Surgery by the Masters*, 1st Ed. St. Louis: Quality Medical, 2007.]

supratip definition as the differential between dorsal height and domal peak lessens.⁴¹

The domes are characterized in terms of the domal arch width, angle of divergence, and degree of symmetry.^{23,44} It is important to relate the lateral crura, domes, and medial crura together in the analysis, as modifications made to one will commonly affect the others.^{3,26} For example, reducing the vertical height of the domes using an extended cephalic trim will drop the supratip break on frontal view and enhance tip definition, whereas improperly stabi-

lized medial crura will result in tip projection loss and blunting of the supratip break.^{37,41,45}

Cephalic Trim

This is often the only excisional maneuver performed and is used before placement of the columellar strut. In the case of bulbous or boxy domes that cause paradomal fullness, a cephalic trim is performed by separating the lower lateral cartilages from the upper lateral cartilages at the scroll area and trimming them, leaving at least a 6-mm-wide rim strip. The preservation of strong lower lateral cartilages is particularly important when applying tip-suturing techniques that recruit the lower lateral cartilages to enhance domal shape and height. For instance, transdomal and, to a lesser degree, interdomal sutures medialize the lower lateral cartilages and produce a relative concavity lateral to the lateral genu of the domes. If these maneuvers are performed in the presence of weakened lower lateral crura, alar rim retraction/notching along with external valve insufficiency may ensue. It is important to realize that cephalic trimming intrinsically decreases tip support through disruption of the attachments of the upper and lower lateral cartilages but can be counteracted by tip-suturing techniques and use of supportive strut grafts (Table 3).

Columellar Strut Graft

The columellar strut graft is the next maneuver in the algorithm (Fig. 4). It is approximately 4 ×

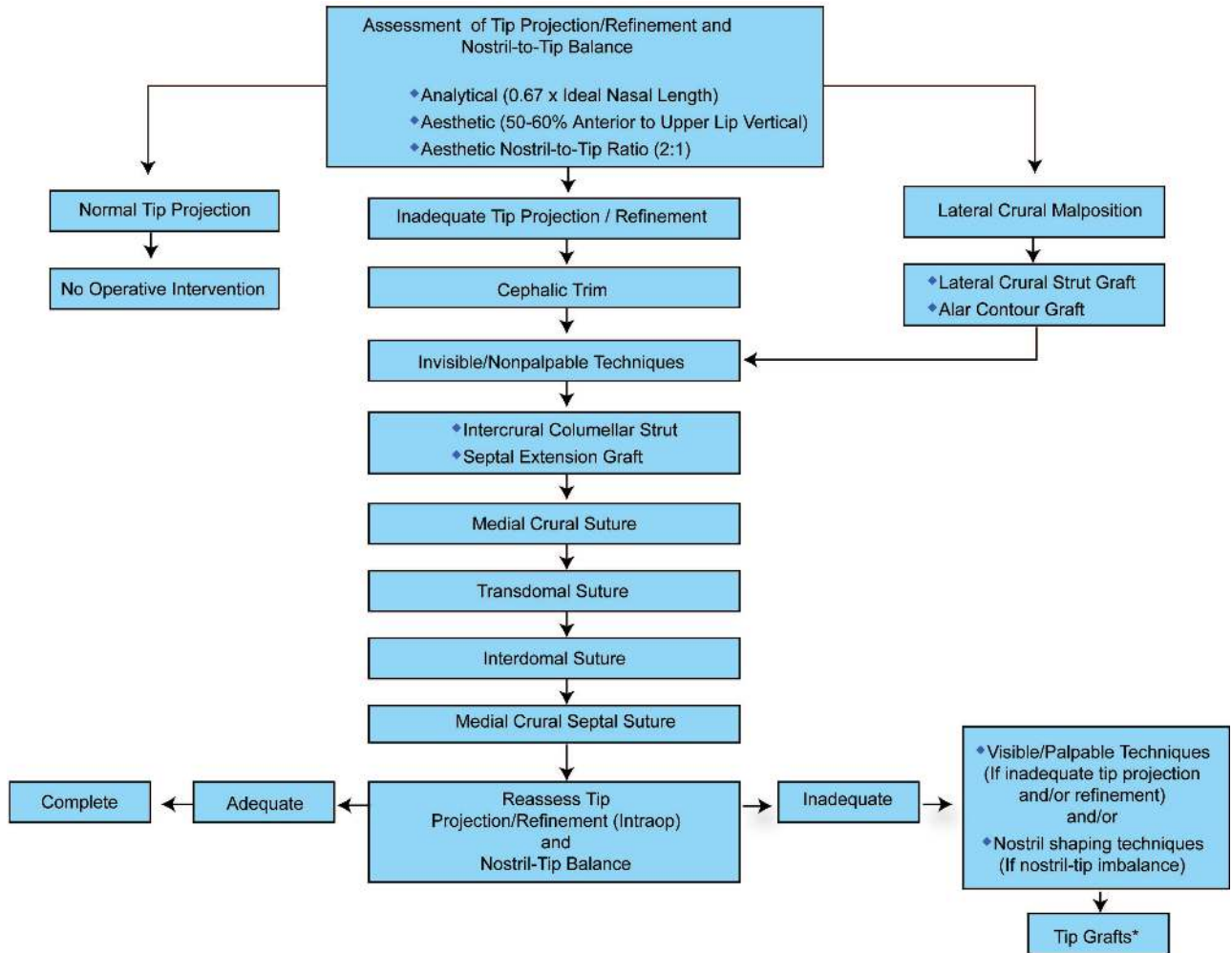


Fig. 4. Simplified algorithm for tip refinement and projection. Visible tip grafts should be used if the tip projection is inadequate after maximizing all suturing and invisible grafting techniques. This situation is more common in men and secondary rhinoplasty and ethnic patients with thick-skinned noses. [Reprinted from J. P. Gunter, R. J. Rohrich, and W. P. Adams, Jr. (Eds.), *Dallas Rhinoplasty: Nasal Surgery by the Masters*, 2nd Ed. St. Louis: Quality Medical, 2007.]

Table 2. Invisible/Nonpalpable Techniques that Influence Tip Refinement and Projection

Technique	Tip Refinement	Tip Projection
Cephalic trim	+	↓
Columellar strut	+	↑
Septal extension graft	+	↑
Medial crura suture	+	↑ / ↓
Transdomal suture	+	↑ / ↓
Interdomal suture	±	↑ / ↓
Medial crura septal suture	+	↑ / ↓
Alar base resection	Neutral	↓

25 mm in size, strengthens the existing nasal tip support, and can provide an additional increase in tip projection. It is also used to equalize and maintain the shape of the medial crura, to change the degree of columellar show, and to refine the infratip columella-lobule region. Most commonly,

the columellar strut graft is invisible between the medial crura but can be made visible when increased columellar show and infratip lobular augmentation are required. It serves an important role in maintaining the additive changes that result from the various tip-suturing techniques.

Two basic types of columellar strut grafts exist: floating and fixed. The floating strut graft is most commonly used; it is inserted between or caudal to the medial crura and is seated 2 to 3 mm anterior to the nasal spine. The medial crura are secured to the strut graft at the junction of the medial crura with the middle crura (medial crural suture). Two additional sutures (interdomal sutures) are often placed anterior to the first suture to affix the medial portions of the domes to the strut, thus helping to camouflage the graft and

Table 3. Key Points for Improving Tip Refinement and Projection

1. Adequate tip projection is defined as when 50 to 60% of the tip lies anterior to the most projecting point of the upper lip.
2. The open approach allows for more direct and accurate assessment and execution of invisible and nonpalpable tip-suturing and grafting techniques when more than minimal tip refinement and projection is required.
3. The skin and soft-tissue envelope should be dissected as close as possible to the cartilaginous framework, and debulking of the tip should be avoided. This will lessen postoperative edema and potential vascular embarrassment.
4. In a patient with thick, sebaceous skin, alterations to the cartilaginous framework should be more aggressive to produce adequate tip definition and projection.
5. One should expect to lose some tip projection intraoperatively through detachment of tip-supporting structures, but when properly applied invisible/nonpalpable techniques are used, this can be counteracted.
6. Great care should be taken to preserve the existing anatomical integrity of the tip-supporting structures. Unnecessary excisions of cartilage and soft tissue should be avoided and are rarely indicated in primary rhinoplasty.
7. Overreduction of the nasal dorsum to give the illusion of improved tip projection is a misguided approach and can lead to a worsening nasal deformity that will require more complex corrective techniques.
8. Columellar struts are the mainstay in providing a stable and strong nasal base that will allow for more liberal use of other tip-suturing techniques.
9. Suturing techniques should be incremental, starting with the medial crural suture to secure and stabilize the columellar strut. Transdomal sutures are commonly required and are a powerful tool in simultaneously controlling tip projection and definition. Medial crural septal sutures may be placed to affect tip rotation and drooping.
10. The skin envelope should be redraped after each suture is placed to assess for modifications needed in position or degree of tightness.
11. Nostril-to-tip imbalances must be assessed preoperatively and reassessed intraoperatively because a preexisting disproportion may be exaggerated by augmenting the tip and failing to address the nostril proper.
12. If the desired tip projection and refinement are not achieved using available invisible/nonpalpable tip-suturing and grafting techniques, more visible/palpable cartilage grafts may be used. These include an assortment of tip grafts that can be fashioned from cephalic trim, septal, or conchal cartilage remnants.

making it invisible and nonpalpable. The floating columellar strut graft can provide 1 to 2 mm of additional tip projection. When 3 mm or more of tip projection is needed, a fixed strut graft may be used. This can be harvested from costal cartilage, notched at the portion abutting the nasal spine, and fixed in place using a threaded Kirschner wire.

Septal Extension Graft

In an effort to improve control and maintenance of tip projection in cases of midvault collapse, Byrd et al.¹³ described the septal extension graft. This is a graft that can be extended from a spreader graft position, a batten graft, or a direct septal extension type beyond the anterior septal angle into the interdomal space (Fig. 5). The upward angle of the graft is often 45 degrees, and the length of the tip portion averages 6 mm. The graft is fixed inferior to the divergence of the middle crura and to a second point of fixation interdomally. This graft more precisely controls the differential between the domal height and the nasal dorsum plane (commonly 6 to 10 mm).

Guyuron and Varghai⁴⁶ described the “tongue-and-groove technique” as an effective method with which to create and maintain tip projection when nasal lengthening is also required. Bilateral spreader grafts that extend beyond the caudal septum are sutured to the septum, and a columellar

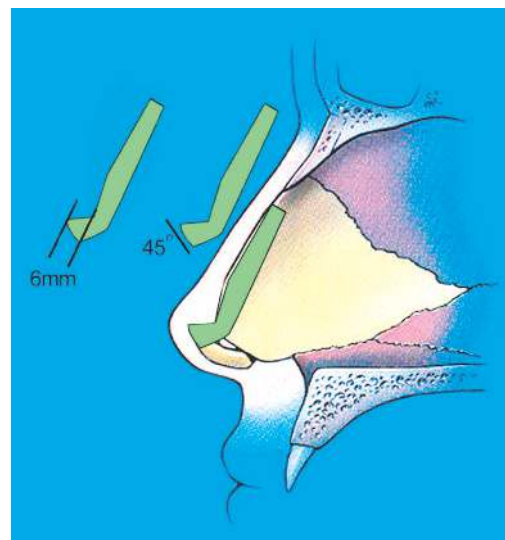


Fig. 5. Septal extension graft (spreader type). (From Byrd, S., Andochick, S., Copit, S., and Walton, K. G. Septal extension grafts: A method of controlling tip projection, rotation, and shape. *Plast. Reconstr. Surg.* 100: 999, 1997.)

strut graft is positioned between the groove created by the spreader grafts.⁴⁶

Medial Crural Suture

Medial crural sutures are the first sutures placed and can be used to correct medial crural asymmetries, to reduce flaring, and to control the overall width of the columella (Fig. 6, *above*). The

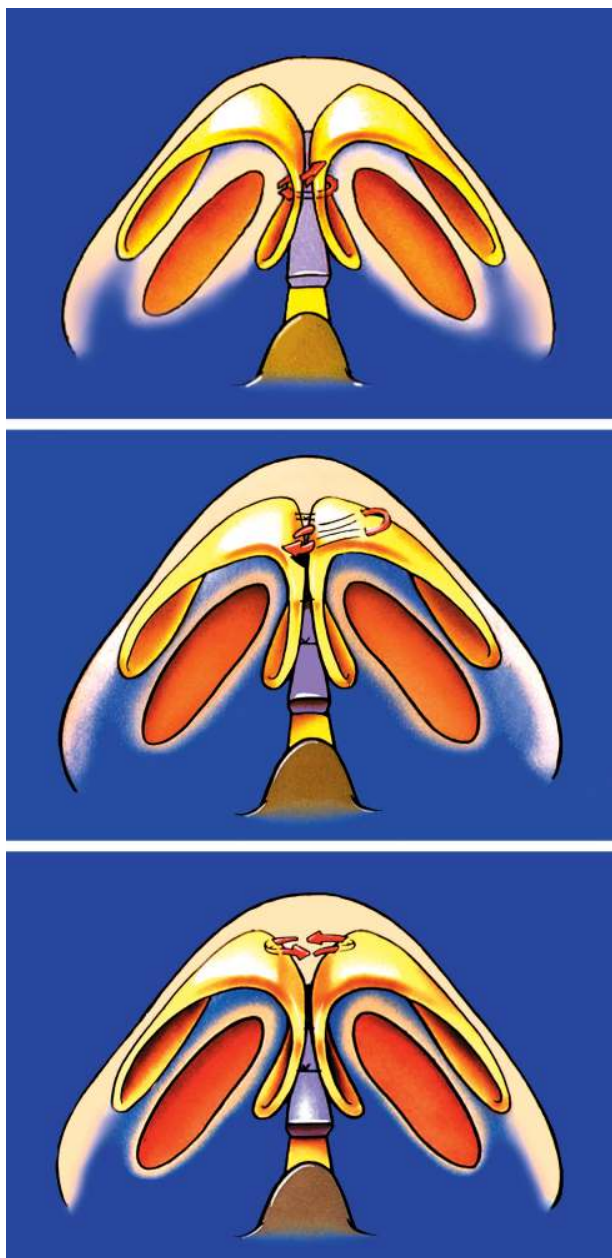


Fig. 6. (Above) Medial crural suture. (Center) Transdomal suture. (Below) Interdomal suture. (From Rohrich, R. J., and Muzaffar, A. R. Rhinoplasty in the African-American patient. *Plast. Reconstr. Surg.* 111: 1322, 2003.)

positioning of the medial crural suture is dictated by the underlying deformity and intended goal. If flaring is to be altered, the suture should be placed in the region of the footplates. When the goal is to correct columellar convexities and asymmetries, the suture should be placed at the apex of that convexity.

Most commonly, medial crural sutures are placed in the middle third of the medial crura to

fixate a columellar strut. This can increase both tip projection and tip strength simultaneously as the medial crura are elevated toward the anterior septal angle. These maneuvers are often required before other tip sutures are placed because the columellar strut/medial crural region acts as a point of stability in the nasal tripod and can limit the dynamic effects suture techniques have on the cartilaginous framework.^{3,26} As with any tip-suturing technique, the degree of tightening is proportional to the intensity of the effect.

Transdomal Suture

Transdomal sutures are placed usually after the nasal base has been stabilized using medial crural sutures with a columellar strut graft. This is a horizontal mattress suture that is placed through the lateral and medial aspects of the domes (Fig. 6, center).

The entry and exit sites of the mattress suture are important because, as the suture is placed farther away from the dome apex, greater lateral crural concavity and tip projection are produced, depending on the amount of suture tightening. Differential placement of this suture can be used to correct domal asymmetries of position and shape. For instance, caudal or cephalad placement of the suture will rotate the lateral crura.²⁶ The transdomal suture is a powerful suturing technique, and care should be taken to avoid creating unnecessary tension on the lateral crura, creating excess concavity adjacent to the lateral genu, and creating more tip projection than indicated.

Interdomal Suture

This is a horizontal mattress suture placed between the domal segments of the middle crura of the lower lateral cartilages (Fig. 6, below). This suture is rarely indicated without concomitant transdomal sutures and, when used in isolation, can potentially *decrease* tip projection by flattening the domes. Transdomal sutures can be placed to achieve interdomal narrowing through tying of the suture tails to each other to duplicate the effect of an interdomal suture.

The interdomal suture technique reduces the angle of domal divergence, narrows the tip-defining points, can further camouflage a columellar or septal extension graft, can enhance the infratip lobule, and increases projection. When placed in the caudal portion of the domes, it can also rotate the lateral crura caudally.²⁶ When improperly placed, the interdomal suture can have deleterious effects on tip shape by unifying the tip-defin-

ing points, reducing domal definition, and excessively narrowing the nasal tip.

Medial Crural Septal Suture

Medial crural septal sutures secure the middle crura to the caudal septum and can be used to reduce or increase nasal tip projection, depending on placement. One or more sutures can be used, and each consists of a three-point suture that captures both medial crura and the caudal septum. Asymmetric placement on the medial crura can assist in symmetry by “clocking” (rotating) one crus toward the other and stabilizing them to the septum. If the medial crura are anchored to a more anterior position on the caudal septum, the tip will rotate in a cephalad direction and tip projection will increase. Conversely, if the medial crura are fixed to the more posterior portion of the caudal septum, the tip will rotate caudally, tip projection will decrease, and the columellar-labial angle and nasolabial angle will become more acute. If tension is placed on the medial crura at the antero-caudal septal position, columellar retraction may occur.

The medial crural septal suture is often indicated in the aging and drooping tip for its effects on tip rotation and projection. Similar effects can be achieved by suturing the medial crura to a fixed columellar strut graft or a septal extension graft,¹³ which may be indicated when the caudal septum is resected and suturing of the medial crura to the new septal position would cause columellar retraction.

Depressor Septi Nasi Muscle

The depressor septi nasi muscle may decrease tip projection by pulling the tip caudally and posteriorly. Resection and/or transposition of the muscle is indicated when hyperdynamic nasal tip ptosis and underprojection are noted preoperatively, and can be accomplished intraorally⁴¹ before completion of other maneuvers or early in the operative sequence during intercrural dissection. The exact role of this muscle in nasal tip shape and position is still under investigation, as other maneuvers that rotate the tip and affect its projection may confound the importance of the depressor muscle.⁴⁷

Nostril-Lobule Imbalance

This step in the algorithmic approach often comes after the nasal tip modifications above are complete. When preoperative nostril-tip disproportion is recognized, the surgeon should be observant of the dynamic changes that have been made to this imbalance intraoperatively. When a large nostril/small tip disproportion is present, a three-stitch tip procedure plus nostril sill/alar wedge resection can be used to reduce the size of the nostril.⁴² When a short nostril is present, there is often lobular excess, and a soft triangle excision with or without transdomal sutures to elongate the nostril apices is required.³⁹ Care must be taken to avoid exaggeration of a short nostril deformity, which can result from maneuvers that increase projection and/or augment the infratip lobule without concomitant techniques that elongate the nostril proper.³⁹

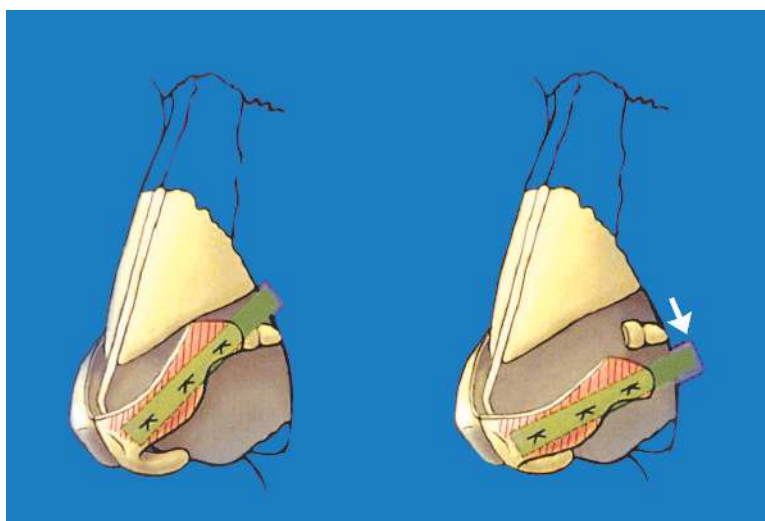


Fig. 7. The lateral crural strut graft can be used to strengthen weak lateral crura and/or to reposition lateral crura caudally.

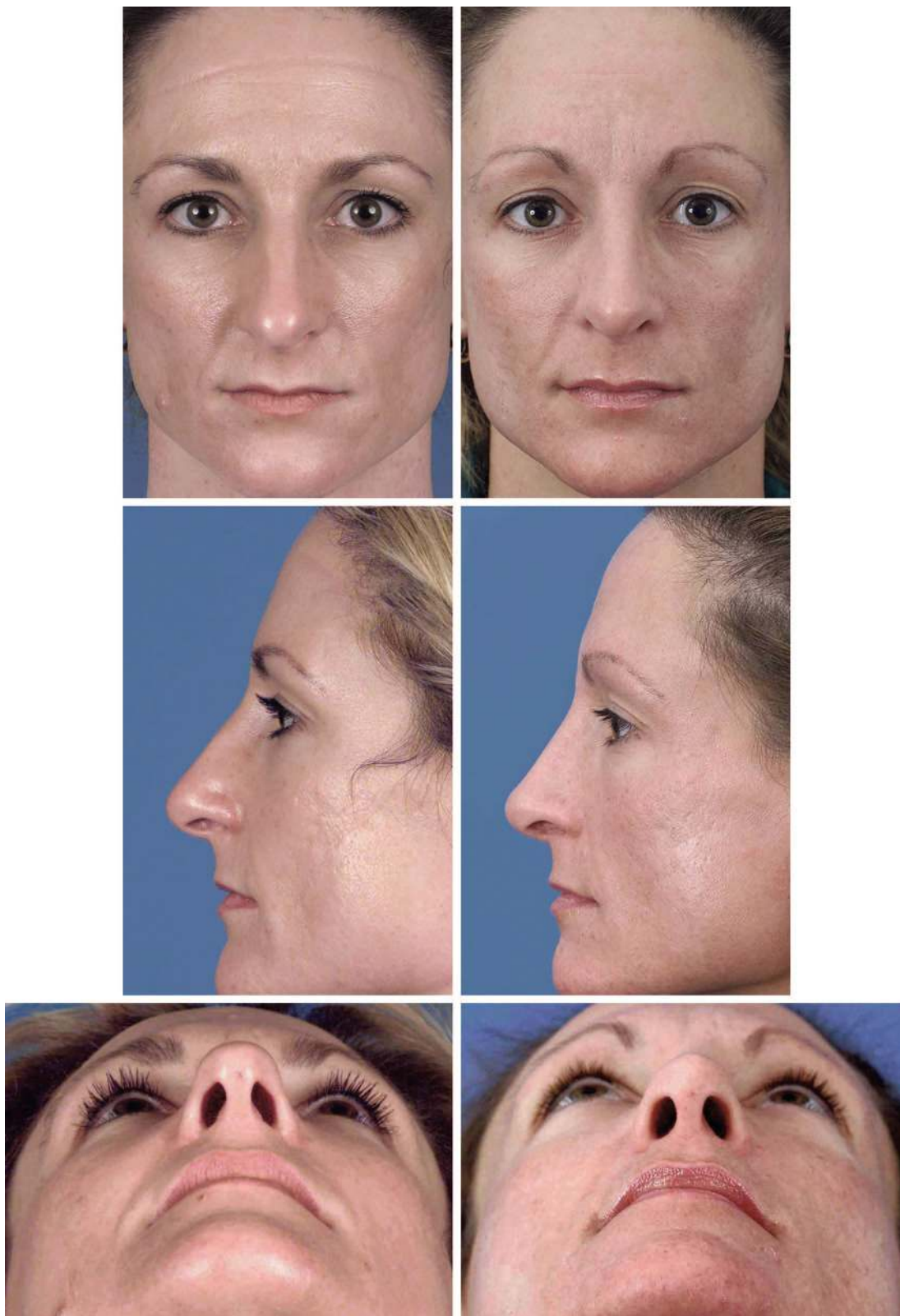

Fig. 8. Preoperative (*left*) and postoperative (*right*) views (12 months) of the patient in case 1, who underwent primary rhinoplasty reveal nasal tip refinement with appropriate projection. (Photographs courtesy of Rod J. Rohrich, M.D., University of Texas Southwestern Medical Center.)

Lateral Crural Strut Grafts and Alar Contour Grafts

Lateral crural strut grafts⁴⁸ are commonly placed to reorient and/or stabilize the alar arch,⁴⁸ such that the lateral crura lie in the same plane with respect to their caudal and cephalic margins.⁴⁰ When the caudal margin of the lateral crura is oriented below the cephalic margin (lower lateral cartilage malposition), a parenthesis tip⁴⁹ can result, which frequently requires lateral crural repositioning with the use of a nonpalpable lateral crural strut graft (frequently with transection of the accessory chain) in addition to other tip-shap-

ing techniques (Fig. 7). If excessive lateral crural convexities or concavities are present but tip projection and balance have been achieved, lateral crural strut grafts or alar contour grafts⁵⁰ can be used to provide support and to prevent future loss of alar rim integrity. The source for lateral crural strut grafts, in order of preference, is septal, conchal, and/or costal cartilage. The medial edge of the graft can extend to the lateral genu or domal apex, depending on the desired effect on tip shape, the alar arch, and domal projection. Alar contour grafts, if indicated, are placed toward the end of the operation.

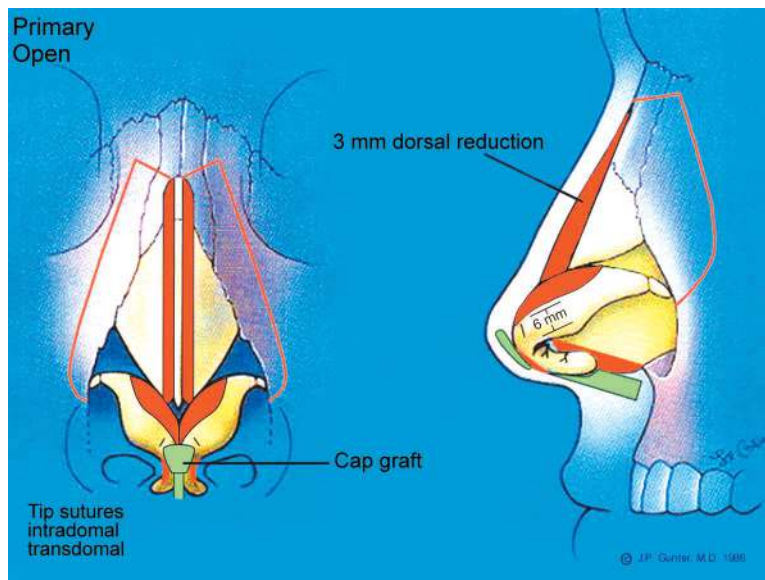


Fig. 9. Case 1. Gunter graphics demonstrating the operative procedure.

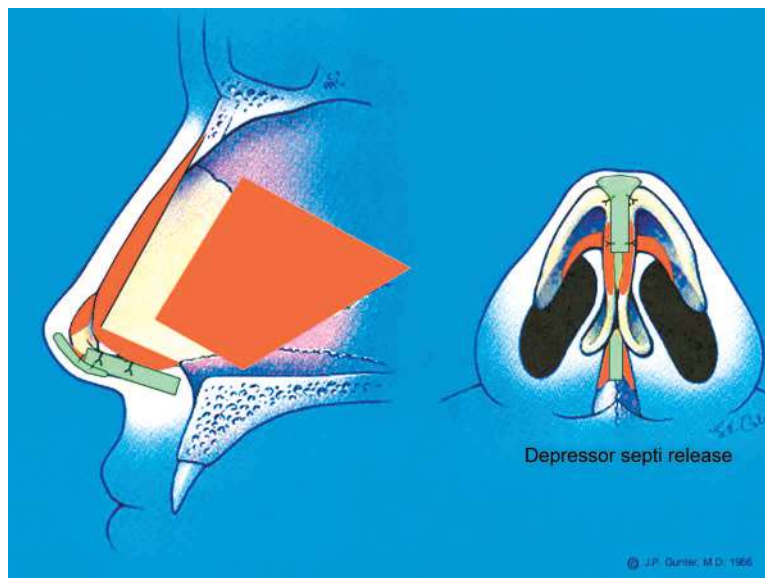


Fig. 10. Gunter graphics demonstrating the operative procedure.

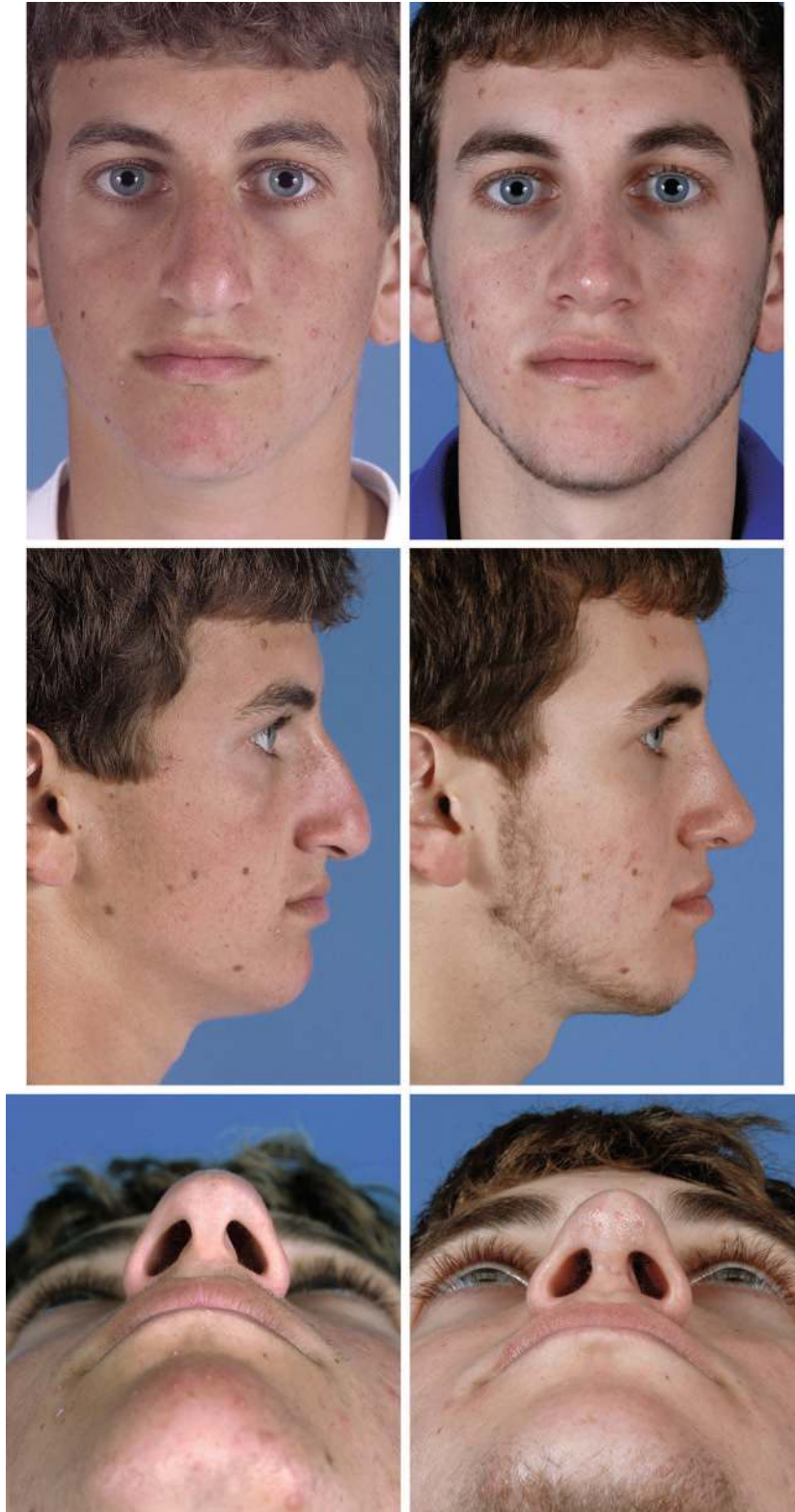


Fig. 11. (Left) Preoperative views of the patient in case 2, with a significant osseocartilaginous dorsal hump, dorsal septal deviation, and excess infratip lobule. (Right) Postoperative views at 12 months demonstrate a normal tip-nasal dorsum relationship, refined tip, and appropriate tip rotation/projection. (Photographs courtesy of Rod J. Rohrich, M.D., University of Texas Southwestern Medical Center.)

Final Assessment and Refinement

The shape and projection of the nasal tip are assessed critically before and after redraping of the skin envelope. The balance between the nasal dorsum and the tip-defining points is scrutinized to control the supratip break. Tip-defining points should project approximately 6 to 10 mm over the nasal dorsum in female patients.⁵¹ Asymmetry and/or contour deformities (visible and/or palpable) are corrected using suture adjustments (including removal, and/or replacements) in an incremental fashion. Large dorsum-tip discrepancies can often be the result of an inadequate columellar

strut and/or a poorly positioned medial crural septal suture. Smaller discrepancies can be caused by poorly executed transdomal sutures and/or interdomal sutures.

If the final tip projection is not adequate despite the incremental application of all the aforementioned suturing and grafting techniques, meticulously placed grafts (often crushed/bruised) that may be palpable and/or visible can be placed, such as onlay tip grafts. These can be applied using cephalic trim remnants, or septal or conchal cartilage. The dimensions of these grafts are critical, because supratip, infratip, and domal landmarks

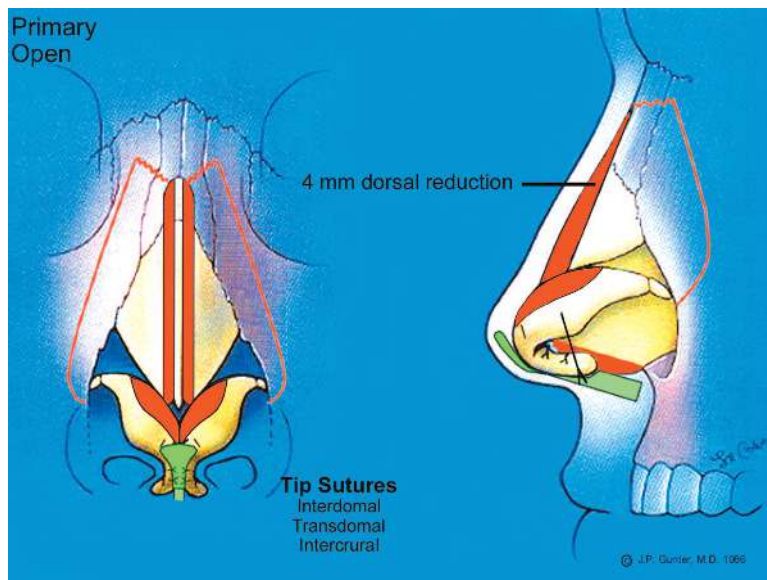


Fig. 12. Case 2. Gunter graphics demonstrating the operative procedure.

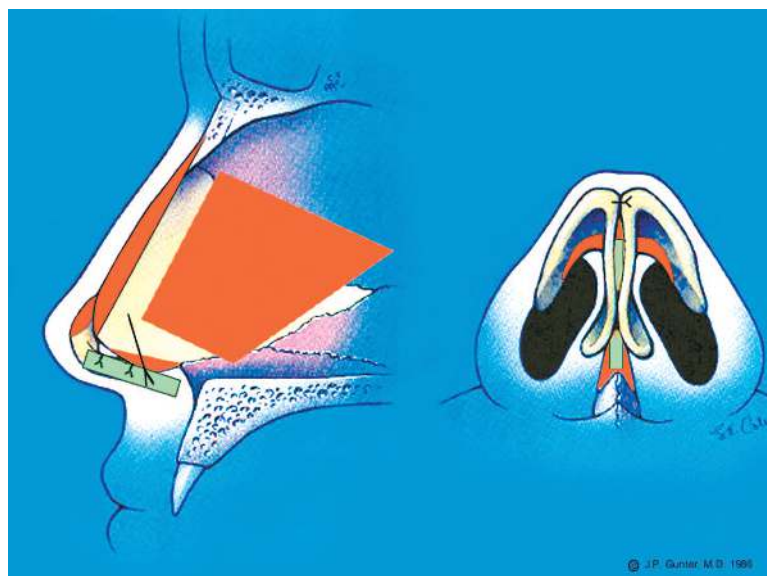


Fig. 13. Gunter graphics demonstrating the operative procedure.

can become blunted if these grafts are not accurately curved at anatomical breakpoints. In addition, grafts that may initially appear hidden may become visible with time as the skin envelope becomes less edematous. Nostril-tip balance should also be reassessed and corrected, when indicated, with appropriate nostril-shaping techniques along with other final tip adjustments.

CASE REPORTS

Case 1

A 35-year-old woman presented with complaints of a dorsal hump and a wide, poorly defined nasal tip that was “too low” (Fig. 8). Findings on nasal analysis included a wide midvault and slight dorsal hump (3 mm); a slightly dependent, moderately bulbous nasal tip with asymmetric alar cartilages; large nostril-to-small tip/lobule imbalance; excess columellar show; hyperactive depressor septi nasi muscle; and caudal septal deviation.

The operative plan (Figs. 9 and 10) included the following: open rhinoplasty approach through a transcolumellar incision with infracartilaginous extensions; septoplasty and cartilaginous graft harvesting; caudal septal resection; 3-mm component dorsal reduction; cephalic trim leaving symmetric alar cartilages and a 6-mm rim strip; a floating columellar strut graft for tip complex stability and correction of medial crural weakness and asymmetry; interdomal and transdomal sutures; cap graft to enhance tip projection and soften tip contour; depressor septi muscle release and transposition; and bilateral percutaneous lateral osteotomies (low-to-low).

Twelve-month postoperative photographs are shown in Figure 8. The patient was pleased with the aesthetic result and improvement. The tip is appropriately rotated and shaped, and the bulbous tip has been corrected with creation of aesthetically pleasing tip contour using invisible/nonpalpable tip suturing techniques. A “visible” cap graft to soften the tip was added.

Case 2

An 18-year-old male patient did not like the size of his nose and the manner in which it drooped. He also complained about his wide and indistinct nasal tip, in addition to the function of his right-sided nasal airway (Fig. 11).

Findings on nasal analysis included significant osseocartilaginous dorsal hump (4 mm at greatest point); wide bony nasal pyramid, midvault, and midface; dorsal deviation with right septal deviation; poorly defined nasal tip with wide angle of divergence and domal arch; vertically oriented and wide lower lateral crura; and dependent tip with insufficient infralobular breakpoints and excess infratip lobule, giving the appearance of poor tip projection.

The operative plan (Figs. 12 and 13) included the following: open rhinoplasty approach by means of a transcolumellar incision with bilateral infracartilaginous extensions; 4-mm component dorsal reduction; septoplasty and cartilaginous graft harvesting; caudal septal resection; bilateral percutaneous lateral osteotomies (low-to-low); cephalic trim leaving a 6-mm rim strip; floating columellar strut graft with medial crural suturing (intercrural); tip refinement with interdomal and transdomal sutures; columellar-septal suture (medial crural strut construct sutured to caudal septum); and infralobular onlay graft.

Twelve-month postoperative photographs show a smooth, straight nasal dorsum with consistent tip projection and tip shape; markedly improved tip rotation has been successfully achieved. Aesthetic nasal tip contours and breakpoints have

been created by both invisible and visible grafting and suturing techniques.

CONCLUSIONS

We have presented a review of nondestructive, predictable, reliable, and incremental techniques that can achieve concomitant tip refinement and projection. Understanding the importance of proper preoperative evaluation, intraoperative assessment and reassessment, and the individual and additive effects of tip-modification maneuvers is paramount to a successful outcome. Used alone or in combination according to an algorithmic approach, the aesthetic goals can be obtained with reproducibility. More conspicuous, aggressive, destructive, or excisional techniques can be obviated using this approach.

Rod J. Rohrich, M.D.

Department of Plastic Surgery
University of Texas Southwestern Medical Center
1801 Inwood Road
Dallas, Texas 75390-9132
rod.rohrich@utsouthwestern.edu

ACKNOWLEDGMENT

The authors would like to express their deep gratitude to Holly P. Smith for assistance with the images used in this article.

REFERENCES

- Adams, W. P., Jr., Rohrich, R. J., Hollier, L. H., Minoli, J., Thornton, L. K., and Gyimesi, I. Anatomic basis and clinical implications for nasal tip support in open versus closed rhinoplasty. *Plast. Reconstr. Surg.* 103: 255, 1999.
- Rohrich, R. J., Gunter, J. P., and Friedman, R. M. Nasal tip blood supply: An anatomic study validating the safety of the transcolumellar incision in rhinoplasty. *Plast. Reconstr. Surg.* 95: 795, 1995.
- Tebbetts, J. B. Shaping and positioning the nasal tip without structural disruption: A new systematic approach. *Plast. Reconstr. Surg.* 94: 61, 1994.
- Tebbetts, J. B. Secondary tip modification: Shaping and positioning the nasal tip using nondestructive techniques. In J. B. Tebbetts (Ed.), *Primary Rhinoplasty: A New Approach to the Logic and the Techniques*. St. Louis: Mosby, 1998. Pp. 261–440.
- Janecke, J. B., and Wright, W. K. Studies on the support of the nasal tip. *Arch. Otolaryngol.* 93: 458, 1971.
- Beekhuis, G. J., and Colton, J. J. Nasal tip support. *Arch. Otolaryngol. Head Neck Surg.* 112: 726, 1986.
- McCollough, E. G., and Mangat, D. Systematic approach to correction of the nasal tip in rhinoplasty. *Arch. Otolaryngol.* 107: 12, 1981.
- Rich, J. S., Friedman, W. H., and Pearlman, S. J. The effects of lower lateral cartilage excision on nasal tip projection. *Arch. Otolaryngol. Head Neck Surg.* 117: 56, 1991.
- Petroff, M. A., McCollough, E. G., Hom, D., and Anderson, J. R. Nasal tip projection. *Arch. Otolaryngol. Head Neck Surg.* 117: 783, 1991.
- Shamoun, J., and Rohrich, R. J. Nasal tip support: An anatomic study. Presented at the Plastic Surgery Senior Residents Conference, San Diego, Calif., May 22–25, 1993.

11. Gunter, J. P. The merits of the open approach in rhinoplasty. *Plast. Reconstr. Surg.* 99: 863, 1997.
12. Rohrich, R. J., and Muzaffar, A. R. A plastic surgeon's perspective. In I. T. Romo, III, and A. Millman (Eds.), *Aesthetic Facial Plastic Surgery: A Multidisciplinary Approach*. New York: Thieme, 1999.
13. Byrd, S., Andochick, S., Copit, S., and Walton, K. G. Septal extension grafts: A method of controlling tip projection, rotation, and shape. *Plast. Reconstr. Surg.* 100: 999, 1997.
14. Guyuron, B. Dynamics of rhinoplasty. *Plast. Reconstr. Surg.* 88: 970, 1991.
15. Tebbetts, J. B. The next dimension: Rethinking the logic, sequence, and techniques of rhinoplasty. In J. P. Gunter, R. J. Rohrich, and W. P. Adams, Jr. (Eds.), *Dallas Rhinoplasty: Nasal Surgery by the Masters*, Vol. 1, 1st Ed. St. Louis: Quality Medical, 2002. Pp. 219–253.
16. Gunter, J. P., and Hackney, F. L. Basic nasal tip surgery: Anatomy and technique. In J. P. Gunter, R. J. Rohrich, and W. P. Adams, Jr. (Eds.), *Dallas Rhinoplasty: Nasal Surgery by the Masters*, Vol. 1, 2nd Ed. St. Louis: Quality Medical, 2007. P. 303.
17. Rohrich, R. J., Adams, W. P., and Deuber, M. A. Graduated approach to tip refinement and projection. In J. P. Gunter, R. J. Rohrich, and W. P. Adams, Jr. (Eds.), *Dallas Rhinoplasty: Nasal Surgery by the Masters*, Vol. 1, 1st Ed. St. Louis: Quality Medical, 2002. Pp. 333–358.
18. McCollough, E. G., and English, J. L. A new twist in nasal tip surgery: An alternative to the Goldman tip for the wide or bulbous lobule. *Arch. Otolaryngol.* 111: 524, 1985.
19. Tardy, M. E., Jr., and Cheng, E. Transdomal suture refinement of the nasal tip. *Facial Plast. Surg.* 4: 317, 1987.
20. Daniel, R. K. Rhinoplasty: Creating an aesthetic tip. *Plast. Reconstr. Surg.* 80: 775, 1987.
21. Daniel, R. K. Rhinoplasty: A simplified, three-stitch, open tip suture technique. Part I: Primary rhinoplasty. *Plast. Reconstr. Surg.* 103: 1491, 1999.
22. Baker, S. R. Suture contouring of the nasal tip. *Arch. Facial Plast. Surg.* 2: 34, 2000.
23. Rohrich, R. J., and Adams, W. P., Jr. The boxy nasal tip: Classification and management based on alar cartilage suturing techniques. *Plast. Reconstr. Surg.* 107: 1849, 2001.
24. Gruber, R. P. Advanced suture techniques in rhinoplasty. In J. P. Gunter, R. J. Rohrich, and W. P. Adams, Jr. (Eds.), *Dallas Rhinoplasty: Nasal Surgery by the Masters*, Vol. 1, 2nd Ed. St. Louis: Quality Medical, 2007. P. 411.
25. Behmand, R. A., Ghavami, A., and Guyuron, B. Nasal tip sutures part I: The evolution. *Plast. Reconstr. Surg.* 112: 1125, 2003.
26. Guyuron, B., and Behmand, R. A. Nasal tip sutures part II: The interplays. *Plast. Reconstr. Surg.* 112: 1130, 2003.
27. De Carolis, V. The infradome graft: A new technique to improve dome reshaping in rhinoplasty. *Plast. Reconstr. Surg.* 102: 864, 1998.
28. Guyuron, B., Poggi, J. T., and Michelow, B. J. The subdomal graft. *Plast. Reconstr. Surg.* 113: 1037, 2004.
29. Gunter, J. P., and Rohrich, R. J. External approach for secondary rhinoplasty. *Plast. Reconstr. Surg.* 80: 161, 1987.
30. Gonzales-Ulloa, M., and Stevens, E. The role of chin correction in profileplasty. *Plast. Reconstr. Surg.* 41: 477, 1968.
31. Byrd, H. S., and Hobar, P. C. Rhinoplasty: A practical guide for surgical planning. *Plast. Reconstr. Surg.* 91: 642, 1993.
32. Rohrich, R. J., Janis, J. E., and Kenkel, J. M. Male rhinoplasty. *Plast. Reconstr. Surg.* 112: 1071, 2003.
33. Rohrich, R. J., and Muzaffar, A. R. Rhinoplasty in the African-American patient. *Plast. Reconstr. Surg.* 111: 1322, 2003.
34. Daniel, R. K. Hispanic rhinoplasty in the United States with emphasis on the Mexican American nose. *Plast. Reconstr. Surg.* 112: 244, 2003.
35. Rohrich, R. J., and Ghavami, A. The Middle Eastern nose. In J. P. Gunter, R. J. Rohrich, and W. P. Adams, Jr. (Eds.), *Dallas Rhinoplasty: Nasal Surgery by the Masters*, Vol. 2, 2nd Ed. St. Louis: Quality Medical, 2007. P. 1139.
36. Rohrich, R. J., and Ghavami, A. Rhinoplasty for middle eastern noses. *Plast. Reconstr. Surg.* (in press).
37. Johnson, C. M., and Godin, M. S. The tension nose: Open structure rhinoplasty approach. *Plast. Reconstr. Surg.* 95: 43, 1995.
38. Rohrich, R. J., Deuber, M. A., and Adams, W. P., Jr. Pragmatic planning and postoperative management. In J. P. Gunter, R. J. Rohrich, and W. P. Adams, Jr. (Eds.), *Dallas Rhinoplasty: Nasal Surgery by the Masters*, Vol. 1, 1st Ed. St. Louis: Quality Medical, 2002. Pp. 72–104.
39. Gunter, J. P., and Hackney, F. L. Clinical assessment and facial analysis. In J. P. Gunter, R. J. Rohrich, and W. P. Adams, Jr. (Eds.), *Dallas Rhinoplasty: Nasal Surgery by the Masters*, Vol. 1, 2nd Ed. St. Louis: Quality Medical, 2007. P. 105.
40. Guyuron, B., Ghavami, A., and Wishnek, S. M. Components of the short nostril. *Plast. Reconstr. Surg.* 116: 1517, 2005.
41. Toriumi, D. M. New concepts in nasal tip contouring. *Arch. Facial Plast. Surg.* 8: 156, 2006.
42. Rohrich, R. J., Huynh, B., Muzaffar, A. R., Adams, W. P., Jr., and Robinson, J. B. Importance of the depressor septi nasi muscle in rhinoplasty: Anatomic study and clinical application. *Plast. Reconstr. Surg.* 105: 376, 2000.
43. Daniel, R. K. Rhinoplasty: Large nostril/small tip disproportion. *Plast. Reconstr. Surg.* 107: 1874, 2001.
44. Rohrich, R. J., and Griffin, J. R. Correction of intrinsic nasal tip asymmetries in primary rhinoplasty. *Plast. Reconstr. Surg.* 112: 1699, 2003.
45. Guyuron, B., DeLuca, L., and Lash, R. Supratip deformity: A closer look. *Plast. Reconstr. Surg.* 105: 1140, 2000.
46. Guyuron, B., and Varghai, A. Lengthening the nose with a tongue-and-groove technique. *Plast. Reconstr. Surg.* 111: 1533, 2003.
47. Ghavami, A., Janis, J. E., and Guyuron, B. Regarding the treatment of dynamic tip ptosis using botulinum toxin A. *Plast. Reconstr. Surg.* 118: 263, 2006.
48. Gunter, J. P., and Friedman, R. M. Lateral crural strut graft: Technique and clinical applications in rhinoplasty. *Plast. Reconstr. Surg.* 99: 943, 1997.
49. Sheen, J. H., and Sheen, A. P. *Aesthetic Rhinoplasty*, 2nd Ed. St. Louis: Mosby, 1987, Pp. 252–272.
50. Rohrich, R. J., Ranieri, J., Jr., and Ha, R. Y. The alar contour graft: Correction and prevention of alar rim deformities in rhinoplasty. *Plast. Reconstr. Surg.* 109: 2495, 2002.
51. Byrd, H. S., Burt, J. D., El-Musa, K. A., and Yazdani, A. Dimensional approach to rhinoplasty: Perfecting the aesthetic balance between the nose and chin. In J. P. Gunter, R. J. Rohrich, and W. P. Adams, Jr. (Eds.), *Dallas Rhinoplasty: Nasal Surgery by the Masters*, Vol. 1, 2nd Ed. St. Louis: Quality Medical, 2007. P. 135.